CAJA COSTARRICENSE DE SEGURO SOCIAL
HOSPITAL SAN JUAN DE DIOS
AREA DE GESTIÓN DE BIENES Y SERVICIOS
SUB AREA DE CONTRATACION ADMINISTRATIVA

22 de octubre 2020
SCASC-389-2020

Señores Proveedores

ASUNTO: Compra 2020LA-000061-2102 "MALLAS DE POLIESTER, DISPOSITIVO ABSORBIBLE.

Estimados señores:

Mediante la presente, les informo que la nueva fecha de Apertura es para el **05/noviembre/2020** a la 9:00 a.m.; además adjunto copia de los oficios CL - 0061-08-20 y CL-00066-10-2020 suscrito Dr. Royner Montero Carvajal, Coordinador Comisión Cirugía Laparoscópica, de acuerdo a consulta realizada por los Proveedores ELEMED Y EUROCIENCIA.(adjunto consultas para mejor entender).

Aviso adjunto al Cartel en la página de la CCSS dirección https://www.ccss.sa.cr/licitaciones

Licda. Genie Alejandra Valverde S.
Coordinadora a.i .Sub Área de Contratación Administrativa

Archivo
2020LA-000061-2102
klindor

CAJA COSTARRICENSE DE SEGURO SOCIAL
Hospital San Juan de Dios
Sección Cirugía
Teléfonos: 2547-8000 / Ext.: 8656
Correo electrónico: hriveral@ccss.sa.cr

27 de agosto del 2020
CL-0061-08-2020

Licenciado
Carlos Andrés Araya Jiménez
Coordinador Sub-Área de Contratación Administrativa
Área de Gestión Bienes y Servicios

Asunto: Solicitud de Subsanación 2020LA-000061-2102 "Mallas de Poliéster y Dispositivo absorbible para fijación de mallas"

Estimado Licenciado:

En atención a su correo electrónico referente a solicitud de aclaración al cartel de licitación indicado en el epígrafe, esta Comisión de Cirugía Laparoscópica procedió analizar la solicitud plantea por la Casa Comercial ELEMED y acepta la modificación al cartel en el **ítem # 3**, quedando de la siguiente forma:

Código: 2-94-02-2962

DISPOSITIVO ABSORBIBLE PARA FIJACION DE MALLAS PARA REPARACION DE HERNIAS. DISPOSITIVO DE 32 a 36 CM PARA FIJACION DE MALLAS EN ABORDAJE LAPAROSCOPICO.

Especificaciones

- ✓ Dispositivo de 32 a 36 cm para fijación de mallas en abordaje laparoscópico.
- ✓ Cargado con clips o gotas compuestas al menos por copolímero de ácido glicólico y láctico, o adhesivo de alta adherencia, absorbibles y / o Biocompatible, para utilizar con trócar al menos de 5 mm.
- ✓ Dispositivo con 20 disparos como mínimo a 45 disparos máximo.

Sin otro particular, se despide.

Atentamente,

COMISION CIRUGIA LAPAROSCOPICA

Dr. Royner Montero Carvajal
Coordinador

COMISION CIRUGIA HSJD LAPAROSCOPICA

Ci: Archivo
Hrl/061.08*20

CAJA COSTARRICENSE DE SEGURO SOCIAL
Hospital San Juan de Dios
Sección Cirugía
Teléfonos: 2547-8000 / Ext.: 8656
Correo electrónico: hriveral@ccss.sa.cr

175 ANIVERSARIO HOSPITAL San Juan de Dios

21 de octubre del 2020
CL. 0066-10-2020.

Licenciado
Andrés Araya Jiménez
Coordinador Sub-Área de Contratación
Área de Gestión Bienes y Servicios

ASUNTO: Respuesta solicitud de Ampliación del cartel Concurso 2020LA-000061-2102

Estimado Licenciado:

En atención a la solicitud planteada por parte de la Empresa Eurociencia, esta Comisión procede analizar dicha petición y acepta la ampliación en el ítem # 2, quedando de la siguiente manera:

Código: 2-12-02-0073

Ítem # 2: MALLA DE POLIESTER TRIDIMENSIONAL O POLIPROPILENO PARA USO LAPAROSCÓPICO DE 25X20CM.

Especificaciones

- ✓ Malla multifilamento tridimensional de poliéster.
- ✓ Componente hidrofílico absorbible de colágeno, glicol de polietileno y glicerol para evitar adherencias y permitir el contacto con viseras.
- ✓ Dimensiones de 25 por 20cm. (+/-3).
- ✓ Una macro porosidad de 1,5mm a 2mm, biocompatible, con un tamaño de poro de 2,55mm x 1,73mm; con una porosidad media del 97%.
- ✓ Grosor de la malla es de 0.57 a 2.0mm.
- ✓ Esterilizada por rayos gama.

Sin otro particular se despide.

Atentamente,

COMISIÓN CIRUGIA LAPAROSCÓPICA

Dr. Royner Montero Carvajal
Coordinador

COMISION CIRUGIA HSJD LAPAROSCOPICA

Cc: Archivo
gnd/0066.10.20

Elemed
Tecnología para el bienestar
COSTA RICA

Alajuela, 23 de Julio 2020.
EM-1107-2020.

Dr. Royner montero Carvajal
Coordinador Comisión Cirugía Laparoscópica
Hospital San Juan de Dios.
Caja Costarricense de Seguro Social.

ASUNTO: RECURSO DE OBJECIÓN AL CARTEL DEL PROCEDIMIENTO LICITACION ABREVIADA 2020LA-000061-2102 MALLAS DE POLIESTER Y DISPOSITIVO ABSORBIBLE PARA FIJACION DE MALLAS

Quien suscribe, José Fernando Esquivel Jiménez, mayor, soltero, ingeniero en electromedicina, cédula de identidad 206500128 en mi condición de Apoderado Generalísimo de ELEMED S.A (Electrónica Médica Costa Rica), cédula jurídica número 3101758557, numero de proveedor 29805 de la Caja Costarricense de Seguro Social, con el debido respeto me presento ante este Despacho como potencial oferente del concurso del epígrafe a interponer en tiempo y forma Recurso de Objeción.

LEGITIMACIÓN

Conforme lo establecido en la Ley de Contratación Administrativa (LCA) artículos 81 y 82 y lo señalado en su reglamento (RLCA), artículo 178, podrá interponer recurso de objeción cualquier potencial oferente.

Elemed S.A (Electrónica Medica) es la empresa que ostenta representación de marca Advanced Medical Solutions, empresa que fabrica el dispositivo fijador de mallas de muy alta calidad y beneficios para los pacientes y profesionales de la salud.

Como tal nos encontramos debidamente legitimados para impugnar aspectos que puedan restringir la libre concurrencia, principio de raigambre constitucional y que como tal es de acatamiento obligatorio para los órganos y entes estatales.

Elemed
Tecnología para el bienestar
COSTA RICA

SGS PYME COSTA RICA

SOBRE LO OBJETADO

Nos presentamos en tiempo y en forma para objetar:

CONDICIONES ESPECÍFICAS DE LA COMPRA

Ítem 3: Dispositivo absorbible para fijación de mallas para reparación de hernias. Dispositivo de 36 cm para fijación de mallas en abordaje laparoscópico

Especificaciones:

Dispositivo de 36 cm para fijación de mallas en abordaje laparoscópico.
Cargado con clips compuestos al menos por copolímero de ácido glicólico y láctico, absorbibles, para utilizar con trocar al menos de 5 mm.
Dispositivo con 20 a 25 clips.

Sabemos que la Administración busca dispositivos de gran calidad y que le den seguridad y beneficios en general.

En los procedimientos laparoscópicos donde se utilizan dispositivos de anclaje es conocido que los pacientes presentan dolor posoperatorio después de la cirugía en los cuales pueden llegar a sufrir dolores crónicos. En la actualidad a nivel mundial se desarrollan altas tecnologías para disminuir el dolor de los pacientes, esto atreves de anclajes líquidos y controlados, con fuerte fijación de la malla, reduciendo el riesgo de las complicaciones postoperatorias comunes: Neuralgia, parestesia o trauma en los tejidos.

Por lo expuesto, solicitamos a la Administración, según el Principio de Eficiencia y Eficacia de la Ley de Contratación Administrativa y el Inciso e del Artículo 8 de su Reglamento, se considere, valore y permita dentro de esta licitación, la posibilidad de entregar Dispositivos Laparoscópicos con adhesivo de alta adherencia de 45 disparos y de uso quirúrgico, con una cánula de largo de 32 cm. Y además que se permita que el dispositivo sea absorbible y/o Biocompatible.

Por lo anterior de la manera más respetuosa recomendamos a la Administración la siguiente redacción

Elemed
Tecnología para el bienestar
COSTA RICA

Ítem 3: Dispositivo absorbible para fijación de mallas para reparación de hernias. Dispositivo de 32 cm a 36 cm para fijación de mallas en abordaje laparoscópico

Especificaciones:

- Dispositivo de 32 cm a 36 cm para fijación de mallas en abordaje laparoscópico.
- Cargado con clips o gotas compuestas al menos por copolímero de ácido glicólico y láctico, o adhesivo de alta adherencia, absorbibles y / o Biocompatible, para utilizar con trocar al menos de 5 mm.
- Dispositivo con 20 disparos como mínimo a 45 disparos máximo.

Análisis del Punto 1.

Dispositivo de 36 cm para fijación de mallas en abordaje laparoscópico.

El largo que posee el dispositivo Liquid Band Fix 8, el cual es de 32 cm, es ideal para los procesos de fijación de malla por su diseño y facilidad de angulación gracias al líquido de cianocrilato de gran fijación, el cual ayuda a una mejor postura del profesional en el momento de aplicarlo en el área correspondiente ya que al ser un líquido no necesita las angulaciones comunes que se deben realizar para poder fijar la malla; al contrario tiene **mayor facilidad de movimiento** en cualquier punto donde desee colocar el adhesivo quirúrgico, por esta razón el largo es ideal para la buena manipulación del dispositivo.

Análisis del punto 2.

Cargado con clips compuestos al menos por copolímero de ácido glicólico y láctico, absorbibles, para utilizar con trocar al menos de 5 mm.

En nuestra línea, de argumentos, buscamos en todo caso, propiciar a las pacientes tecnologías que eliminen o minimicen el dolor postoperatorio, es por ello que solicitamos ampliar este punto para lograr involucrar a la mayor cantidad de oferentes y que la Administración tenga las mejores tecnologías y productos de calidad para beneficio del área de salud con reducción de tiempos de hasta un 30% en sala de cirugía con fijación precisa y rápida con beneficios post-operatorios para los pacientes.

Análisis del punto 3:

Elemed
Tecnología para el bienestar
COSTA RICA

Dispositivo con 20 a 25 clips.

La tecnología de Advanced Medical y su dispositivo Fix8, posee un número mayor de disparos, debido a que su uso además de la fijación de la malla, permite fijar el peritoneo y hasta logra cerrar las incisiones de los trocars de 5mm con el mismo dispositivo, permitiendo reducir los tiempos y costos del nosocomio y a la vez aprovechando todo todos los disparos del dispositivo con grandes beneficios y reducción de tiempo en suturas y más.

Nuestro producto es una tecnología de avanzada, por lo que consideramos que la administración valore incluir dentro de sus inventarios, productos que brinde distintos beneficios (asociados directamente a los pacientes), por ejemplo, la fijación del peritoneo como se observa en la siguiente imagen:

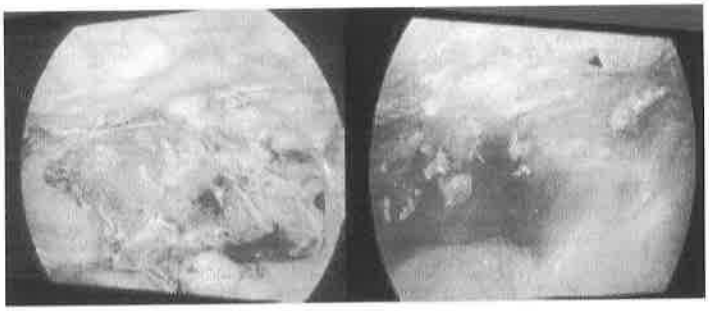

Imagen 1. Fijación del Peritoneo. (Casos en CR).

Gracias a esta bondad que ofrece el producto, el tiempo en el quirófano se reduce más de un 30%, además eliminando posibles complicaciones dentro del mismo, por la tecnología que la fijación liquida permite.

Algunas de las ventajas adicionales de la fijación por medio de adhesivo de alta fijación tenemos las siguientes:

- Fijación fuerte y segura de la malla
- Aplicación precisa y controlada
- Tiempo rápido de fijación de menos de 10 segundos
- No hay penetración del tejido en la malla de fijación
- No causa trauma mecánico
- No pegajoso / Punta del aplicador atraumática

Es altamente importante mencionar que el Fix8 representa el futuro en anclajes, nuestra tecnología ya

Elemed
Tecnología para el bienestar
COSTA RICA

ha sido probada en todo Europa por más de 5 años, y en Costa Rica se han realizado cerca de 50 casos desde el año 2019 a la fecha en distintos Hospitales como es el caso del Hospital del Trauma y en el caso del Hospital San Rafael de Alajuela.

Por último, nos permitimos en adjuntar estudios clínicos, que avalan el uso de este tipo de dispositivos.

Notificaciones: Tel: (506) 4350-0200/ 70232333 Fax:(506) 4350-0201 Correo Electrónico: info.costarica@electronicamedica.com. Domicilio en Rio Segundo de Alajuela, 700 mts este del Aeropuerto Internacional Juan Santamaría, Oficentro Plaza Aeropuerto.

Atentamente:

JOSE FERNANDO ESQUIVEL JIMENEZ (FIRMA)
Firmado digitalmente por JOSE FERNANDO ESQUIVEL JIMENEZ (FIRMA)
Fecha: 2020.07.24 14:54:03 -06'00'

Ing. Fernando Esquivel Jiménez
Apoderado General
Electrónica Medica Costa Rica.

Original Article

Eur Surg
DOI 10.1007/s10353-015-0367-z

european surgery
ACA Acta Chirurgica Austriaca

TAPP surgery with mesh fixation and peritoneal closure using n-butyl-2-cyanoacrylate (LiquiBand®FIX8™)—initial experience

R. Mittermair · G. Jenic · R. Kolenik · C. Sorre

Received: 12 October 2015 / Accepted: 14 October 2015
© Springer-Verlag Wien 2015

Summary

Introduction Laparoscopic procedures in groin hernia repair have been established since many years. Adhesive techniques for mesh fixation in the transabdominal pre-peritoneal (TAPP) procedure are now being increasingly discussed. Currently, there are three categories of adhesives available: synthetic adhesives (cyanoacrylate), biological products (e.g. fibrin glue) and genetically produced polymer protein adhesives.

The objective of this observation study was to evaluate the adhesive technique for mesh fixation and peritoneal closure using n-butyl-cyanoacrylate.

Material and method Between January and February 2015, 20 consecutive male patients underwent TAPP surgery with mesh fixation and peritoneal closure with cyanoacrylate. The investigations encompassed complication rate and postoperative pain after 6 days and 3 months.

Results Postoperative complication rate was low, one haematoma and one bulging. According to a standardised visual analogue scale (VAS 0–10), the average preoperative pain score was 2.8 (0–7), 1.2 (0–3) after 6 days and 0.1 (0–2) after 3 months. The mean operation time was 69 min. No hernia recurrence was detected during follow-up.

Conclusion Our initial experience shows that mesh fixation and peritoneal closure using n-butyl-2-cyanoacrylate is save and sufficient.

Prof. R. Mittermair, MD, FACS, FEBS (✉) · G. Jenic · R. Kolenik · C. Sorre
Department of Surgery,
Medical Center Klinikum Klagenfurt am Wörthersee,
Feschnigstrasse 11,
9020 Klagenfurt, Austria
e-mail: reinhard.mittermair@kabeg.at

Keywords TAPP · Mesh fixation · Adhesive technique · Cyanoacrylate

Introduction

The vast majority of hernias occur in the inguinal region, and the high incidence of this condition means that inguinal hernia repair is the most frequently performed surgical procedure in the United States [1] and in Europe [2]. Non-fixation of the mesh seems the safest and least traumatic method, but there have been reports of higher mesh mobility, lower tensile strength, and increased risk of recurrence, if left unfixated [3]. However, in a systematic review with fixation of the mesh by tacks in both transabdominal pre-peritoneal (TAPP) and totally extraperitoneal (TEP) compared with no fixation, the results showed no difference in the risk of recurrence, when the mesh was left unfixated ($p=0.77$) [4]. Guidelines from International Endohernia Society (IEHS) recommend that non-fixation of the mesh during TAPP should be considered in types LI, LII, MI and MII hernias (EHS classification). If the TEP technique is chosen, non-fixation can be considered in all types of hernias, except for the largest defects [5]. The use of fibrin sealant for fixation of the mesh has been shown to decrease postoperative complications in addition to shortening procedure time, compared with using tacks [6]. The EHS guidelines state that fibrin sealant has shown signs of less acute and chronic pain compared with staples for fixation of the mesh [5].

The aim of this study was to evaluate early postoperative pain and feasibility of mesh fixation and peritoneal closure using n-butyl-2-cyanoacrylate in patients undergoing laparoscopic groin hernia repair (TAPP).

Methods

Men aged 18–80 years, classified with American Society of Anesthesiologists (ASA) class I–III were consecutively included. The exclusion criteria were women, inguinoscrotal hernia, presumed poor compliance (language disability, dementia psychiatric disorders etc.) and daily intake of opioids within the last week before operation. Patients with systemic use of steroids or other immunosuppressant medicine were also excluded. Mesh fixation was exclusively performed with the adhesive technique using LiquiBand®FIX8™ (Advanced Medical Solution, Plymouth, UK), an adhesive based on cyanoacrylate. The study included patients with direct or indirect hernias as well as bilateral hernias, whereby sonographically the size of the hernial orifice had to be below 3 cm (Figs. 1, 2). Also, peritoneal closure was performed by adhesive technique using LiquiBand®FIX8™. With regard to the literature, this is the first study describing this type of peritoneal closure. After closure of the peritoneum we deflated the capnopneumoperitoneum and waited for at least 10 min, and then we performed a control laparoscopy. Patients received similar general anaesthetic and analgetic regimens. Analgesic treatment was started immediately after the operation and consisted of paracetamol 1 g intravenously 4 times on postoperative day 1 and paracetamol 500 mg orally 3 times daily for another 4 days. We recorded the preoperative pain and early postoperative pain after 6 days and the late postoperative pain after 3 months in accordance with the visual analogue scale (VAS). During these controls, the patients were also clinically examined and in case of suspected recurrence or questionable clinical results, we performed a sonography.

Surgical technique

The TAPP procedures were performed by experienced laparoscopic surgeons. We used a polypropylene mesh TiO2Mesh™ (BioCer, Bayreuth, Germany) with a pore size of 2.4 mm and a thickness of 0.25 mm, which was adjusted to a size of 13 to 15 cm (Figs. 3, 4). Mesh fixation was performed with LiquiBand®FIX8™ (Figs. 5, 6). To fixate the mesh we installed eight fixation points, while omitting the lateral nerve regions (Fig. 7). Peritoneal closure was implemented with the adhesive technique using LiquiBand®FIX8™ at a reduced intra-abdominal pressure of 8 mmHg (Fig. 8). This usually required five to eight applications. The success of peritoneal adhesion using cyanoacrylate was controlled by relaparoscopy after a minimum waiting period of 10 min, during which intra-abdominal gas was deflated (Fig. 9).

The three trocar sites were injected with local anaesthetic bupivacaine 0.5%, (5 ml). The patients were discharged on the second postoperative day.

Fig. 1 Intraoperative view of an inguinal hernia

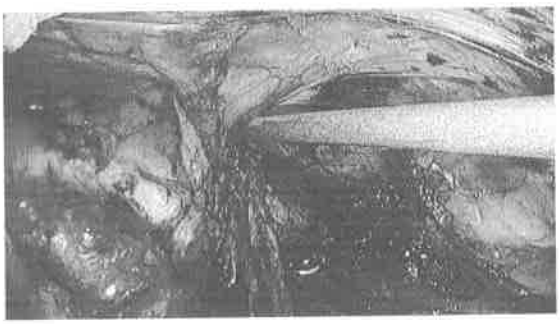

Fig. 2 Instrument shows the region of the inguinal hernia



Fig. 3 Rolled up mesh is introduced intra-abdominal

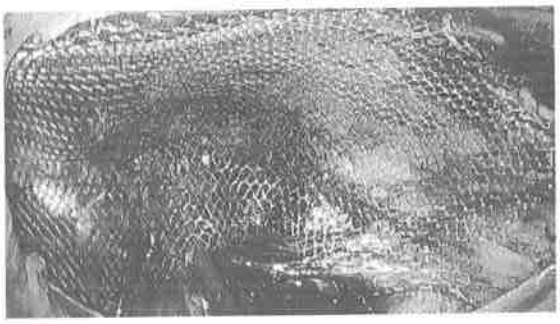

Fig. 4 Positioning of the mesh



Fig. 5 Mesh fixation using the cyanoacrylate glue

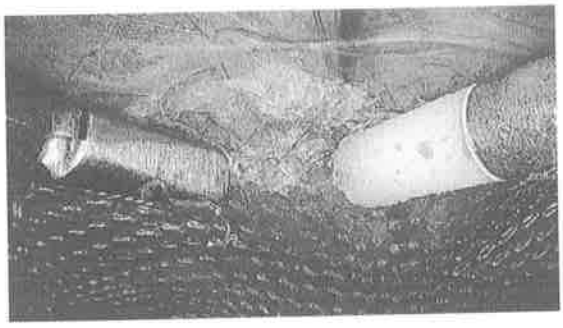

Fig. 6 Close-up view of the cyanoacrylate glue



Fig. 7 Mesh fixation after using the cyanoacrylate glue

Fig. 8 Peritoneal closure using the cyanoacrylate glue technique

Fig. 9 Intraoperative documentation after relaparoscopy (10 min delay): permanent peritoneal closure using the cyanoacrylate glue technique

Results

Between January and February 2015, 20 male patients underwent hernia repair at our department following the TAPP technique. A total of four patients had a hernia on both sides, seven patients only on their right side and nine patients only on their left side. According to a standardised visual analogue scale (VAS 0–10), the average preoperative pain score was 2.8 (0–7), 1.2 (0–3) after 6 days and 0.1 (0–2) after 3 months (Table 1). The mean operation time was 69 min, including delay of 10 min for relaparoscopy. We did not detect any recurrence during postoperative follow-up. In all, one patient showed a bulging, which disappeared after 4 weeks. One patient reported pain (VAS 2) 3 months after operation. The reason therefore was a sonographically detected haematoma. In one case, peritoneal closure was only possible using two LiquiBand®FIX8™ instruments. This occurred during one of the first glue peritoneal closures, so we assumed a technical handling problem. All peritoneal defects had been closed successfully by using the cyanoacrylate glue technique.

Discussion

Standard methods of repair include open (e.g. Lichtenstein procedure) or laparoscopic techniques using a mesh fixated with tissue-penetrating methods (sutures, staples or tacks), non-penetrating methods such as fibrin sealant, or no fixation [6–10]. Major long-term concerns regarding hernia surgery are mainly from open repair techniques and include postoperative chronic pain in 5–20% of patients [11, 12], sexual dysfunction in 9.4% of patients [13], and recurrence in up to 5% of patients [14, 15]. Tissue adhesives have the ability of fixating tissue-to-tissue or tissue-to-mesh, without causing additional damage to the surrounding tissue [16–19]. Tissue adhesives may even enhance wound healing, lower the inflammatory response, be bacteriostatic [19–21], and

Table 1 Postoperative pain according to visual analogue scale

Patients	Right	Left	Bilateral	VAS pre-OP	VAS day 6	VAS month 3	Recurrence	Surgery time in min.
1	1	0	0	2	1	0	0	60
2	1	1	1	2	1	0	0	91
3	0	1	0	2	3	0	0	66
4	0	1	0	3	1	0	0	65
5	1	0	0	5	1	0	0	84
6	0	1	0	2	2	0	0	60
7	0	1	0	2	0	0	0	65
8	1	0	0	1	1	0	0	64
9	1	1	1	3	2	0	0	88
10	0	1	0	5	1	0	0	80
11	1	0	0	4	1	0	0	64
12	0	1	0	1	0	0	0	63
13	1	1	1	1	2	0	0	88
14	0	1	0	3	1	0	0	68
15	1	0	0	5	1	0	0	75
16	0	1	0	7	3	2	0	46
17	0	1	0	2	0	0	0	70
18	1	1	1	3	1	0	0	85
19	0	1	0	1	1	0	0	50
20	1	0	0	2	1	0	0	65

has been shown to lower the reoperation rate [15]. Reduction of pain during the first days after laparoscopic groin hernia repair may shorten the duration of the convalescence period since pain is an important determinant of duration of convalescence [22–24]. Duration of convalescence and sick leave is of major socioeconomic interest because inguinal hernia repair is the most often conducted gastrointestinal surgical procedure [22, 24–26]. Various kinds of tissue sealants have been proposed for the fixation of hernia meshes with the aim of eliminating the aforementioned threats. These products can be divided into three main categories: synthetic glues (e.g. cyanoacrylate based), biologic products (e.g. fibrin sealant) and genetically engineered polymer protein glues [27]. Synthetic glues such as n-butyl-2-cyanoacrylate are promoted for hernia mesh fixation. However, their surgical use is not widely accepted because of reported cytotoxicity and the lack of published studies outlining the potential side effects of cyanaocrylate glue for mesh sealing [28, 29]. Due to good results regarding the dreaded chronic postoperative pain with simultaneously low rates of recurrence, the glue mesh fixation technique is asserting itself more and more [30]. The LiquiBand FIX8™ is a laparoscopic instrument with an n-butyl-2-cyanoacrylate adhesive used to fixate the hernia mesh. This instrument can be used to accurately place anchors applied in liquid form, whereby every one of the 33 prefabricated portions can be precisely dispensed by activating a lever. In experiments on 20 rats in 2007, Fortelny et al. [29] observed micro-abscesses and more complicated mesh integration when using a synthetic glue applied extensively in larger volumes. In 2012, Kukleta et al. [31] published a major series of more than 1300 TAPP operations with mesh fixations using n-butyl-cyanoacrylate. He demonstrated a precise fixation technique with a considerably smaller volume (up to 4 ml per square centimetre), showed excellent mesh integrity without a single mesh or wound infection. He also demonstrated that the excellent biocompatibility of n-butyl-cyanoacrylate was sufficiently tested. The glue based on cyanoacrylate also permits an excellent stability, which is achieved after only a few seconds [31]. Our point of view is that only few dots of cyanoacrylate are necessary for a sufficient mesh fixation and therefore only one LiquiBand FIX8™ instrument is necessary for functionally adequate mesh fixation and for closure of the peritoneal defect.

Conclusion

This study showed that TAPP surgery using the adhesive technique with n-butyl-cyanoacrylate is suitable for mesh fixation and closure of the peritoneal defect. Furthermore, the adhesive technique with n-butyl-cyanoacrylate may presumably contribute to the prevention of chronic postoperative pain.

However, further studies are required to substantiate the usability of n-butyl-cyanoacrylate for both mesh fixation and peritoneal closure.

Conflict of interest

Reinhard Mittermair, Gerhard Jenic, Raimund Kolenik and Christian Sorre declare that they have no conflict of interest.

References

1. Matthews RD, Neumayer L. Inguinal hernia in the 21st century: an evidence-based review. Curr Probl Surg. 2008;45:261–312.
2. Primatesta P, Goldacre MJ. Inguinal hernia repair: incidence of elective and emergency surgery, readmission and mortality. Int J Epidemiol. 1996;25:835–9.
3. Katkhouda N, Mavor E, Friedlander MH, et al. Use of fibrin sealant for prosthetic mesh fixation in laparoscopic extraperitoneal inguinal hernia repair. Ann Surg. 2001;233:18–25.
4. Sajid MS, Ladwa N, Kalra L, et al. A meta-analysis examining the use of tacker fixation versus no-fixation of mesh in laparoscopic inguinal hernia repair. Int J Surg. 2012;10:224–31.
5. Bittner R, Montgomery MA, Arregui E, et al. Update of guidelines on laparoscopic (TAPP) and endoscopic (TEP) treatment of inguinal hernia (international endohernia society). Surg Endosc. 2015;29:289–321.
6. Fortelny RH, Petter-Puchner AH, Glaser KS, et al. Use of fibrin sealant (Tisseel/Tissucol) in hernia repair: a systematic review. Surg Endosc. 2012;26:1803–12.

7. Campanelli G, Pascual MH, Hoeferlin A, et al. Randomized, controlled, blinded trial of Tisseel/Tissucol for mesh fixation in patients undergoing Lichtenstein technique for primary inguinal hernia repair: results of the TIMELI trial. Ann Surg. 2012;255:650–7.
8. Matthews RD, Neumayer L. Inguinal hernia in the 21st century: an evidence-based review. Curr Probl Surg. 2008;45:261–312.
9. Petter-Puchner AH, Brunner W, Gruber-Blum S, et al. A systemic review of hernia surgery in SIL (single-incision laparoscopy) technique. Eur Surg. 2014;46:113–7.
10. Fischer S, Zechmeister-Koss I. Is day surgery safe? A systematic literature review. Eur Surg. 2014;46:103–12.
11. Topart P, Vandenbroucke F, Lozac'h P. Tisseel versus tack staples as mesh fixation in totally extraperitoneal laparoscopic repair of groin hernias: a retrospective analysis. Surg Endosc. 2005;19:724–7.
12. Lau H. Fibrin sealant versus mechanical stapling for mesh fixation during endoscopic extraperitoneal inguinal hernioplasty. Ann Surg. 2005;242:670–5.
13. Aasvang EK, Møhl B, Bay-Nielsen M, et al. Pain related sexual dysfunction after inguinal herniorrhaphy. Pain. 2006;122:258–63.
14. Burcharth J, Andresen K, Pommergaard HC, et al. Direct inguinal hernia and anterior surgical approach are risk factors for female inguinal hernia recurrences. Langenbecks Arch Surg. 2014;399:71–6.
15. Helvind NM, Andresen K, Rosenberg J. Lower reoperation rates with the use of fibrin sealant versus tacks for mesh fixation. Surg Endosc. 2013;27:4184–91.
16. Vakalopoulos KA, Daams F, Wu Z, et al. Tissue adhesives in gastrointestinal anastomosis: a systematic review. J Surg Res. 2013;180:290–300.
17. Duarte AP, Coelho JF, Bordado JC, et al. Surgical adhesives: systematic review of the main types and development forecast. Prog Polym Sci. 2012;37:1031–50.
18. Lodi D, Iannitti T, Palmieri B. Management of haemostasis in surgery: sealant and glue applications. Blood Coagul Fibrinolysis. 2012;23:465–72.
19. Lee MGM, Jones D. Applications of fibrin sealant in surgery. Surg Innov. 2005;12:203–13.
20. Ryou M, Thompson CC. Tissue adhesives: a review. Tech Gastrointest Endosc. 2006;8:33–7.
21. ASGE Technology Committee; Bhat YM, Banerjee S et al. Tissue adhesives: cyanoacrylate glue and fibrin sealant. Gastrointest Endosc. 2013;78:209–15.
22. Bay-Nielsen M, Thomsen H, Andersen FH, Bendix JH, Sorensen OK, Skovgaard N, Kehlet H. Convalescence after inguinal herniorrhaphy. Br J Surg. 2004;91:362–7.
23. Pavlin DJ, Chen C, Penaloza DA, Polissar NL, Buckley FP. Pain as a factor complicating recovery and discharge after ambulatory surgery. Anesth Analg. 2002;95:627–34.
24. Callesen T, Klarskov B, Bech K, Kehlet H. Short convalescence after inguinal herniorrhaphy with standardised recommendations: duration and reasons for delayed return to work. Eur J Surg. 1999;165:236–41.
25. Kehlet H, Jensen TS, Woolf CJ. Persistent postsurgical pain: risk factors and prevention. Lancet. 2006;367:1618–25.
26. McCormack K, Wake B, Perez J, Fraser C, Cook J, McIntosh E, Vale L, Grant A. Laparoscopic surgery for inguinal hernia repair: systematic review of effectiveness and economic evaluation. Health Technol Assess. (2005);9:1–203, iii–iv.
27. Cuschieri A. Tissue adhesives in endosurgery. Semin Laparosc Surg. 2001;8:63–8.
28. Jourdan IC, Bailey ME. Initial experience with the use of N-butyl-2-cyanoacrylate glue for the fixation of polypropylene mesh in laparoscopic hernia repair. Surg Laparosc Endosc. 1998;8:291–3.
29. Fortelny RH, Pettert-Puchner AH, Walder N, Mittermayr R, Öhlinger W, Heinze A, Redl H. Cyanoacrylate tissue sealant impairs tissue integration of macroporous mesh in experimental hernia repair. Surg Endosc. 2007;21:1781–5.
30. Fortelny RH, Petter-Puchner AH, May C, Jaksch W, Benesch T, Khakpour Z, Redl H, Glaser KS. The impact of a traumatic fibrin sealant vs. staple mesh fixation in TAPP hernia repair on chronic pain and quality of life: results of a randomized controlled study. Surg Endosc. 2012;26:249–54.
31. Kukleta JF, Freytag C, Weber M, et al. Efficiency and safety of mesh fixation in laparoscopic inguinal hernia repair using n-butyl-cyanoacrylate: long-term biocompatibility in over 1300 mesh fixations. Hernia. 2012;16:153–62.

original article

Eur Surg
DOI 10.1007/s10353-016-0450-0

european surgery
ACA Acta Chirurgica Austriaca

A novel glue device for fixation of mesh and peritoneal closure during laparoscopic inguinal hernia repair: short- and medium-term results

Bernhard Dauser · Alexander Szyszkowitz · Gerald Seitinger · René H. Fortelny · Friedrich Herbst

Received: 20 September 2016 / Accepted: 27 September 2016
© Springer-Verlag Wien 2016

Summary
Background Mesh fixation during transabdominal preperitoneal (TAPP) hernia repair should be done using nonpenetrating fixation devices in order to reduce acute and chronic pain. Beside fibrin sealant, N-butyl cyanoacrylate (NBCA) can be applied. However, there are limited data using NBCA exclusively for fixation of mesh and closure of peritoneum following TAPP repair. We therefore studied a novel laparoscopic fixation device (LiquiBand®Fix8™ by Advanced Medical Solutions, Plymouth, UK) addressing these issues.
Methods A prospective study was performed in two (different tertiary referral) centres in Austria, including patients undergoing TAPP repair between January and May 2015. The aforementioned device was used for fixation of mesh at predefined reference points (rectus muscle, pubic bone, triangle of doom, triangle of pain) and entire closure of peritoneum whenever possible.
Results In a total of 34 (4 female) patients, 40 inguinal hernias were repaired using the TAPP approach. Fixation of mesh at four predefined reference points was successful using a single liquid anchor in 88.1 % (141/160). Thorough closure of peritoneum using NBCA was possible in 36 cases (90.0 %). Twice, additional suturing was done as the device clogged during this step of procedure. Finally, in another 2 patients, the attending surgeon declined using glue at all, as the sigmoid colon attached exerted too much traction. No device-related complication was recorded during 1-year follow-up.
Conclusion Nonpenetrating fixation of mesh during TAPP repair using this novel device is highly effective. In addition, closure of peritoneum using exclusively NBCA is safe and feasible according to our experience

Keywords TAPP repair · Mesh fixation · Peritoneal closure · Minimally invasive surgery · Inguinal hernia · Tissue adhesives

B. Dauser, MD, PhD (✉) · F. Herbst, MD, PhD
Department of Surgery, St John of God Hospital, Vienna, Austria
b.dauser@hotmail.com

A. Szyszkowitz, MD · G. Seitinger, MD
Department of Surgery, St John of God Hospital, Graz, Austria

R. H. Fortelny, MD, PhD
Department of General, Visceral and Oncological Surgery, Wilhelminenspital, Vienna, Austria

Introduction

Nonpenetrating fixation of meshes during transabdominal preperitoneal (TAPP) hernia repair is associated with less acute and chronic pain [1, 2]. According to the (updated) guidelines of the International Endohernia Society (IEHS), fibrin 'glue' should be considered for this step of procedure [3, 4]. However, the strength of mesh fixation is weak and closure of the peritoneum is impossible using fibrin sealant. Butyl esters provide stronger bonds [5], and fixation of meshes using N-butyl cyanoacrylate (NBCA) during TAPP repair proved to be safe and feasible [6, 7]. However, there are still limited data available using NBCA exclusively for fixation of mesh and closure of peritoneum [8].

We therefore performed a prospective study using a novel laparoscopic fixation device (Liquiband®Fix8™ by Advanced Medical Solutions, Plymouth, UK) for fixation of mesh and closure of peritoneum during TAPP repair and present our short- and medium-term results.

Published online: 21 October 2016



Fig. 1 The LiquiBand®-Fix8™ represents a laparoscopic 5 mm nonpenetrating fixation device. Approximately 33 liquid anchors (containing N-butyl-cyanoacrylate) can be applied

Patients and methods

The study was approved by the local ethics committees at St. John of God Hospital in Vienna and Graz (Austria) and registered at www.clinicaltrials.gov (NCT02457728). Written informed consent was obtained from each patient before inclusion into this trial. Patients between 18 and 90 years with uni- or bilateral, inguinal or femoral, primary or recurrent hernias undergoing TAPP repair were included. Exclusion criteria were scrotal hernia, poor compliance (language disability, dementia) or pregnancy. Demographic, peri- and postoperative data were recorded prospectively. BD, AS and GS performed all procedures.

Antibiotic prophylaxis was not performed on a routine base. In case of conventional multiport access, three noncutting trocars were placed at the umbilical level. For single-port surgery the Octo™Port (Dalim SurgNET, Seoul, Korea) was used. Type of access was left to discretion of surgeon in charge. Identification of anatomical landmarks and extent of dissection was performed as recommended by the IEHS [3].

Description of device

The LiquiBand®Fix8™ represents a 5 mm nonpenetrating laparoscopic fixation device (Fig. 1). By pulling the trigger, a well-defined amount of NBCA (0.0125 g) is delivered. In total, approximately 33 such 'liquid anchors' are available (Figs. 2a–c and 3).

Description of surgical technique

The peritoneal incision was made 1 to 2 cm higher up than we used to do before using NBCA. The upper peritoneal flap was not mobilized at all. Success of mesh fixation at four predefined reference points (rectus muscle, pubic bone, triangle of doom, triangle of pain) using a single liquid anchor was recorded. It was left to surgeon's discretion to add liquid anchors for mesh fixation at other locations. Finally, the intraabdominal pressure was reduced to 8 mm Hg to ease approximation of the peritoneal flaps. NBCA was applied to the nonmobilized upper boarder of peritoneum and the lower flap was subsequently pulled over the upper one. Following every single application of NBCA, the peritoneal flaps were compressed for a few seconds (Fig. 2a–c). Several liquid anchors at an interval of less than 1 cm were set using the aforementioned technique, thereby gradually closing the peritoneum. At the end of the procedure, the pneumoperitoneum was released and reestablished after 3 min at 12 mm Hg for study reasons only. The result of the peritoneal closure was reexamined (Fig. 3).

Clinical follow-up was done 6 weeks postoperatively and after 1 year.

Results

In 34 (4 female) patients, 40 TAPP repairs were performed between January and May 2015. The period included our learning curve with the device. Demographic data of patients and procedural details are listed in Table 1. 34 primary inguinal, five recurrent inguinal and a single femoral hernia were seen. TiO2Mesh™ 10 × 15 cm (BioCer Entwicklungs-GmbH; Bayreuth, Germany), 3DMaxTM Light Mesh Extra-Large (C. R. Bard, Inc.; Warwick, RI, USA), VitaMesh™ Blue 10 × 15 cm or C-QUR™ CentriFX Mesh Large (both MAQUET Holding GmbH & Co.KG, Rastatt, Germany) was used in 14, 9, 14 and 3 cases respectively. Results are summarized in Table 2.

Fixation of mesh

Success rate for transporous glue fixation of lightweight macroporous polypropylene meshes accounted for 91.2 % (135/148). In three initial cases, an omega 3 fatty acid-covered mesh was used, applying the glue underneath the mesh. Despite this technical adaptation, fixation with a single liquid anchor was possible only in 50.0 % (6/12), and the abovementioned coated mesh was not used any longer. The reference point itself had no influence on success rate.

Closure of peritoneum

Entire closure of peritoneum was accomplished using 12 (median; range: 8–20) liquid anchors in 36 out of

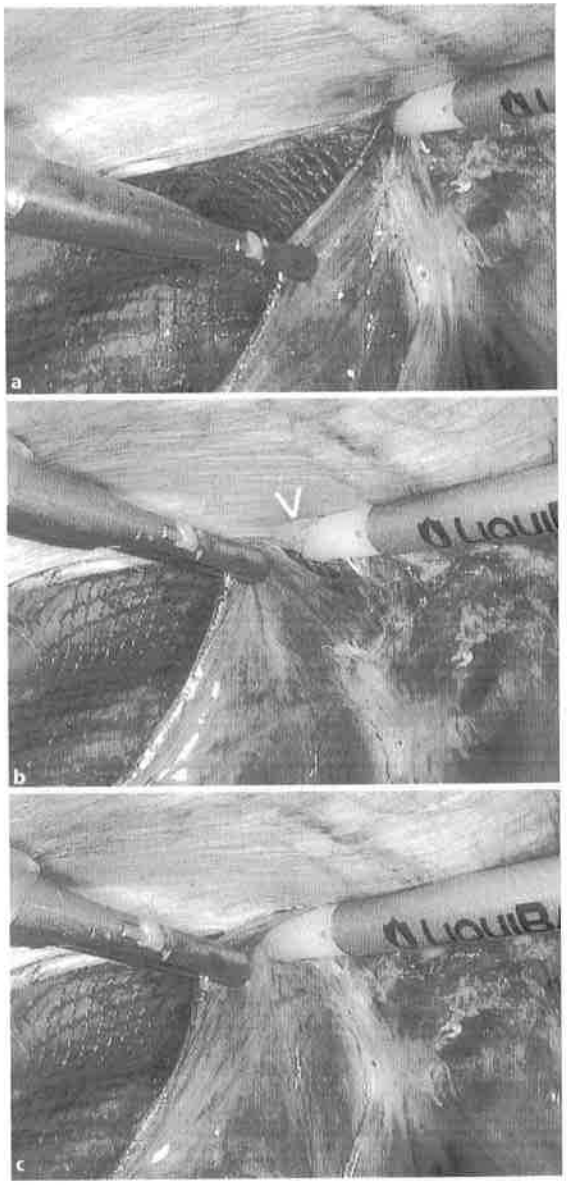

Fig. 2 The lower flap is grasped (a), a dot of glue is applied (>) while approximating the peritoneal layers (b). The flaps are a compressed (c). These steps are repeated, thereby gradually closing the peritoneal gap

40 cases (90.0 %). Twice, the tip of the device clogged during this step and attending surgeon decided to do additional suturing instead of using another glue device. Finally, the same surgeon declined using NBCA for closure of peritoneum in additional two cases, as the sigmoid colon attached exerted too much traction on the lower peritoneal flap.

In six cases (6/34, 17.6 %), a single-port approach was used. In order to reduce clashing of instruments, the shaft of the device was bent without compromising it's function (Fig. 4). Median time for entire closure of peritoneum using the single-port technique was slightly longer compared to the conventional multi-port approach (184 vs. 170 s; $p = 0.104$).

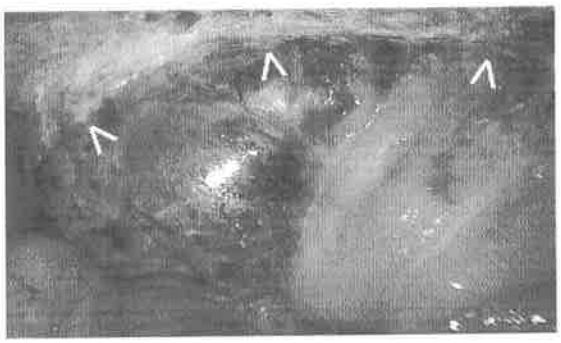

Fig. 3 Final result is shown at the end of procedure. The line of closure is indicated (>)

In total, the tip of the device clogged five times (5/34; 14.7 %), but no other device-related problems were observed. Persistent and complete peritoneal closure was seen in all cases after reestablishment of the pneumoperitoneum at 12 mm Hg.

Patients left hospital on postoperative day 2 (median; range: 1–4). One patient undergoing TAPP repair for right-sided femoral hernia reported enduring pain at 6-weeks clinical follow-up and after 1 year. No other complication was recorded.

Discussion

Fixation of mesh

Penetrating fixation devices such as tacks, staples or straps should not be used for mesh fixation to avoid nerve injuries and adhesions [9, 10]. According to the (updated) guidelines of the IEHS, fibrin glue is recommended for mesh fixation during TAPP repair [3, 4]. However, butyl esters potentially offer some advantages compared to fibrin sealant: stronger bonds are provided for mesh fixation, the peritoneum can be adapted to facilitate suturing and closure of incisional wounds can be done using one and the same agent. Disadvantageously, nonabsorbable impenetrable glue plaques do impair tissue integration [11] and therefore only distinctive dots of 'superglue' should be used. The LiquiBand®Fix8™ delivers a well-defined amount of NBCA addressing this problem and our results demonstrate that nonpenetrating fixation of lightweight macroporous polypropylene meshes is highly effective using this novel device.

Closure of peritoneum

Most surgeons do a running suture and some still use tacks for peritoneal closure to avoid exposure of mesh to the viscera. However, small bowel obstruction after

Table 1 Demographic and perioperative data

Demographic and perioperative data	
Male/female	30/4
Age (years)	57 (20–82)
BMI (kg/m^2)	24.6 (18.0–30.6)
Multiport/single port	28/6
Uni-/bilateral hernia	28/6
Primary/recurrent hernia	35/5

Table 2 Details using N-butyl cyanoacrylate (NBCA) for mesh fixation and peritoneal closure and postoperative data

Mesh fixation using NBCA	
Successful fixation (yes/no)	141/19 (88.1 %)
Peritoneal closure using NBCA	
Successful closure (yes/no)	36/4 (90 %)
Number of liquid anchors needed	12 (8–20)
Time required (s)	170 (60–420)
Device-related problems	
Clogging of device	5/34 (14.7 %)
Postoperative data & complications	
Duration of hospital stay (d)	2 (1–4)
Persistent pain	1

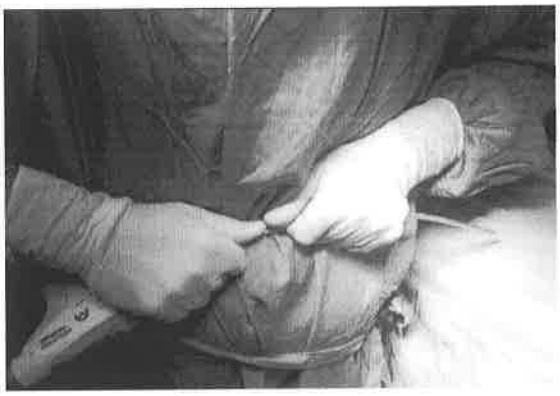

Fig. 4 The device is customized for single-port surgery by bending the shaft without loss of function

TAPP repair due to insufficient closure of peritoneum or entrapment of bowel at displaced tacks may occur in the early postoperative period [12–14]. In addition, self-anchoring barbed sutures—frequently used as knotting is avoided—may also cause intestinal obstruction if the suture cuts through the peritoneum or the thread is left too long [15]. According to our experience, closure of peritoneum using exclusively NBCA is safe and feasible and could be a viable option. In this series, clinical follow-up was done at 6 weeks and after 12 months to rule out any (severe) adverse events related to the technique applied. A single patient reported on persistent pain, but no other complication (e.g. intestinal obstruction) was seen. However, no recommendation can be made concerning the exclusive use of NBCA for peritoneal closure based on our experience and due to limited data available at present [8].

Notably, one surgeon could not accomplish peritoneal closure using NBCA exclusively in 30.8 % (4/13). Twice the device clogged and instead of opening another device, additional suturing was performed. In another two cases, closure of the peritoneum with NBCA was declined as traction to the lower peritoneal flap was assessed to be too high. By performing the peritoneal incision higher up and further reduction of the intraabdominal pressure, this problem can be solved. But this observation indicates that there is a relevant learning curve using this novel device, especially for the peritoneal closure.

Bilateral hernia, closure of skin incisions

In principle, the repair of bilateral hernias with a single device containing approximately 33 liquid anchors is possible. In this series, a median of 12 applications were necessary for closure of peritoneum each side. However, a larger number of loads per device would be beneficial; especially if more (than four) liquid anchors are applied for mesh fixation. In addition, the same device could also be used for closure of skin incisions at the end of the procedure, as cyanoacrylate adhesives offer some benefits: faster closure time, less tissue trauma, no requirement for secondary wound dressing, ease of bathing, no need for further appointments to remove suture material while showing comparable cosmetic results [16, 17].

Single-port surgery

Our results confirm that use of LiquiBand®Fix8™ is also feasible for single-port laparoscopy. This approach was developed during recent years to further decrease surgical access trauma and to avoid visible scars [18]. However, clashing of instruments is a major problem and suturing remains challenging. Using this novel fixation device, these drawbacks may be eliminated by bending the shaft of the device (Fig. 4). As glue is delivered via a flexible catheter, full function is not constrained by this manoeuvre. There was no significant difference concerning time required for peritoneal closure using either a conventional multiport or a single-port approach in our series.

Device-related problems

Clogging of the device was seen in a number of cases (5/34; 14.7 %). This was caused by pressing the tip strongly into the tissue during NBCA application. On inspection, this led to complete occlusion of the dispending cavity in the tip. In addition, 1–2 mm of feeding tube was also blocked. Removing the dispensing cavity and cutting back of tube invariably restored functionality in all cases.

In conclusion, this novel laparoscopic fixation device proved to be a promising alternative for fixation of mesh during TAPP repair. In addition, closure of peritoneum by NBCA only appears to be safe and feasible. Finally, the device can be customized for single-port surgery by bending the shaft without loss of function. We therefore conclude that this novel device represents a viable tool for laparoscopic inguinal hernia repair.

Conflict of interest B. Dauser, A. Szyszkowitz, G. Seitinger, R.H. Fortelny and F. Herbst declare that they have no competing interests.

References

1. Fortelny RH, Petter-Puchner AH, Glaser KS, Redl H. Use of fibrin sealant (Tisseel/Tissucol) in hernia repair: a systematic review. Surg Endosc. 2012;26:1803–12.
2. Sajid MS, Ladwa N, Kalra L, McFall M, Baig MK, Sains P. A meta-analysis examining the use of tacker mesh fixation versus glue mesh fixation in laparoscopic inguinal hernia repair. Am J Surg. 2013;206:103–11.
3. Bittner R, Arregui ME, Bisgaard T, Dudai M, Ferzli GS, Fitzgibbons RJ, Fortelny RH, Klinge U, Kockerling F, Kuhry E, Kukleta J, Lomanto D, Misra MC, Montgomery A, Morales-Conde S, Reinpold W, Rosenberg J, Sauerland S, Schug-Pass C, Singh K, Timoney M, Weyhe D, Chowbey P. Guidelines for laparoscopic (TAPP) and endoscopic (TEP) treatment of inguinal hernia [International Endohernia Society (IEHS)]. Surg Endosc. 2011;25:2773–843.
4. Bittner R, Montgomery A, Arregui ME, Bansal V, Bingener J, Bisgaard T, Buhck H, Dudai M, Ferzli GS, Fitzgibbons RJ, Fortelny RH, Grimes KL, Klinge U, Köckerling F, Kumar S, Kukleta J, Lomanto D, Misra MC, Morales-Conde S, Reinpold W, Rosenberg J, Singh K, Timoney M, Weyhe D, Chowbey P, International Endohernia Society. Update of guidelines on laparoscopic (TAPP) and endoscopic (TEP) treatment of inguinal hernia (International Endohernia Society). Surg Endosc. 2015;29:289–321.
5. Schug-Pass C, Jacob DA, Rittinghausen J, Lippert H, Köckerling F. Biomechanical properties of (semi-) synthetic glues for mesh fixation in endoscopic inguinal hernia repair. Hernia. 2013;17:773–7.
6. Kukleta JF, Freytag C, Weber M. Efficiency and safety of mesh fixation in laparoscopic inguinal hernia repair using n-butyl cyanoacrylate: long-term biocompatibility in over 1,300 mesh fixations. Hernia. 2012;16:153–62.
7. Wang MG, Tian ML, Zhao XF, Nie YS, Chen J, Shen YM. Effectiveness and safety of n-butyl-2-cyanoacyrlate medical adhesive for noninvasive patch fixation in laparoscopic inguinal hernia repair. Surg Endosc. 2013;27:3792–8.
8. Mittermair R, Jenic G, Kolenik R, Sorre C. TAPP surgery with mesh fixation and peritoneal closure using n-butyl-2-cyanoacrylate (LiquiBandFix8TM) – initial experience. Eur Surg. 2016;48:110–4.
9. Tolver MA, Rosenberg J, Juul P, Bisgaard T. Randomized clinical trial of fibrin glue versus tacked fixation in laparoscopic groin hernia repair. Surg Endosc. 2013;27:2727–33.
10. Lovisetto F, Zonta S, Rota E, Mazzilli M, Bardone M, Bottero L, Faillace G, Longoni M. Use of human fibrin glue (Tissucol) versus staples for mesh fixation in laparoscopic transabdominal preperitoneal hernioplasty: a prospective, randomized study. Ann Surg. 2007;245:222–31.
11. Fortelny RH, Petter-Puchner AH, Walder N, Mittermayr R, Ohlinger W, Heinze A, Redl H. Cyanoacrylate tissue sealant impairs tissue integration of macroporous mesh in experimental hernia repair. Surg Endosc. 2007;21:1781–5.
12. Maddern GJ, Rudkin G, Bessell JR, Devitt P, Ponte L. A comparison of laparoscopic and open hernia repair as a day surgical procedure. Surg Endosc. 1994;8:1404–8.
13. The MRC Laparoscopic Groin Hernia Trial Group. Laparoscopic versus open repair of groin hernia: a randomised comparison. Lancet. 1999;354:185–90.
14. Fitzgerald HL, Orenstein SB, Novitsky YW. Small bowel obstruction owing to displaced spiral tack after laparoscopic TAPP inguinal hernia repair. Surg Laparosc Endosc Percutan Tech. 2010;20:e132–e135.
15. Köhler G, Mayer F, Lechner M, Bittner R. Small bowel obstruction after TAPP repair caused by a self-anchoring barbed suture device for peritoneal closure: case report and review of the literature. Hernia. 2015;19:389–94.
16. Chow A, Marshall H, Zacharakis E, Paraskeva P, Purkayastha S. Use of tissue glue for surgical incision closure: a systematic review and meta-analysis of randomized controlled trials. J Am Coll Surg. 2010;211:114–25.
17. Jan H, Waters N, Haines P, Kent A. LiquiBand® Surgical S topical adhesive versus sutures for closure of laparoscopic wounds. A randomized controlled trial. Gynecol Surg. 2013;10:247–52.
18. Macdonald ER, Ahmed I. "Scarless" laparoscopic TAPP inguinal hernia repair using a single port. Surgeon. 2010;8:179–81.

Critical evaluation of an innovative mesh for bilateral transabdominal preperitoneal (TAPP) repair of inguinal hernias

G. Köhler, I. Fischer, R. Kaltenböck, M. Mitteregger, G. Seitinger & A. Szyszkowitz

Hernia
The World Journal of Hernia and Abdominal Wall Surgery

ISSN 1265-4906

Hernia
DOI 10.1007/s10029-018-1786-0

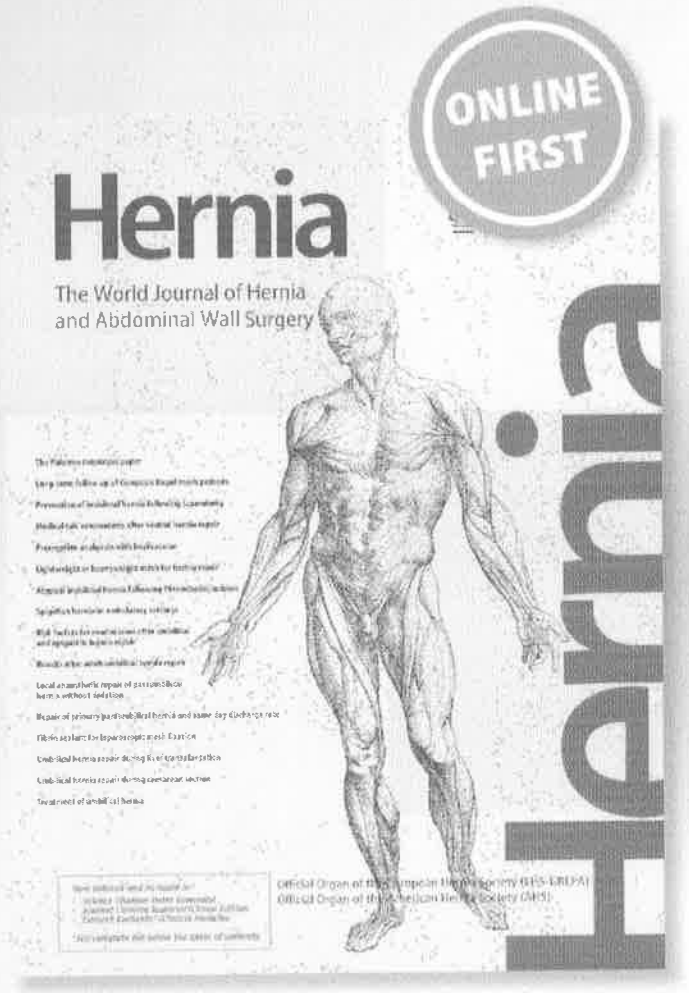

Springer

Your article is protected by copyright and all rights are held exclusively by Springer-Verlag France SAS, part of Springer Nature. This e-offprint is for personal use only and shall not be self-archived in electronic repositories. If you wish to self-archive your article, please use the accepted manuscript version for posting on your own website. You may further deposit the accepted manuscript version in any repository, provided it is only made publicly available 12 months after official publication or later and provided acknowledgement is given to the original source of publication and a link is inserted to the published article on Springer's website. The link must be accompanied by the following text: "The final publication is available at link.springer.com".

Springer

Author's personal copy

Hernia
https://doi.org/10.1007/s10029-018-1786-0

HOW-I-DO-IT

Critical evaluation of an innovative mesh for bilateral transabdominal preperitoneal (TAPP) repair of inguinal hernias

G. Köhler[1,2,3,4,5] · I. Fischer[1,3,4,5] · R. Kaltenböck[1,3,4,5] · M. Mitteregger[6] · G. Seitinger[6] · A. Szyszkowitz[6]

Received: 4 February 2018 / Accepted: 31 May 2018
© Springer-Verlag France SAS, part of Springer Nature 2018

Abstract

Purpose Transabdominal preperitoneal hernia mesh plasty (TAPP) offers significant benefits to patients undergoing bilateral inguinal hernia repair. We evaluated a novel pre-shaped, large-pored, titanium-coated, lightweight polypropylene mesh for bilateral placement as an alternative to two separate meshes.

Methods Thirty-six patients underwent elective surgical repair of bilateral inguinal hernias with the new mesh at three departments of surgery in Linz and Graz, Austria, between May 1, 2015 and June 30, 2017.

Results All operations were completed without intraoperative complications or conversion to open procedures. The mean operation time was 74 min. There were no postoperative procedure-related complications with the exception of one hematoseroma of the spermatic cord. Two symptomatic medial recurrences (2/36 patients = 5.6%, 2/72 hernia repairs = 2.8%, respectively) after supravesical and medial hernia repair with the bilateral mesh were seen at structured follow-up examinations 6 and 12 months postoperatively.

Conclusion Treatment of bilateral inguinal hernias with the newly designed bilateral mesh for TAPP theoretically brings benefits in terms of resistance to forces acting on the mesh. The larger area may decrease the risk for mesh bulging and recurrence, and one large mesh might provide more stable support than two separate meshes overlapping at the midline. The results of our study do not confirm these theoretical benefits regarding a high recurrence rate (2.8%) after treatment of medial hernia defects. We recommend re-designing the mesh with only a small central slit, which would provide a broader mesh bridge with sufficient overlap for all types of inguinal and femoral hernias, including medial and supravesical defects. After the mesh has been re-designed, a new study should evaluate its real benefits before it is marketed.

Keywords Transabdominal preperitoneal patch plasty · TAPP · Groin hernia · Inguinal hernia

Introduction

Inguinal hernia repair, with an incidence of some 5–7%, is the most common surgical procedure worldwide [1, 2]. For this generally elective surgery, laparoscopic approaches and tension-free mesh repairs have become an attractive alternative to open surgery [3]. The simultaneous repair of bilateral hernias is safe, with comparable pain and length of convalescence as for unilateral operations [4].Transabdominal preperitoneal hernia mesh plasty (TAPP) offers a significant benefit for female patients, because reoperation rates after anterior hernia repairs in women are higher than with men. With TAPP, the whole myopectineal orifice of Frucheaud [5] can be overlapped. It also offers benefits to patients undergoing bilateral or recurrent inguinal hernia repair after a previous anterior approach [6]. The open posterior preperitoneal

✉ G. Köhler
gernot.koehler@ordensklinikum.at

1 Department of General and Visceral Surgery, Congregation Hospital (Sisters of Charity), 4010 Linz, Austria

2 Department of Surgery, Paracelsus Medical University, Salzburg, Austria

3 Academic Teaching Hospital, Medical University of Vienna, Vienna, Austria

4 Academic Teaching Hospital, Medical University of Graz, Graz, Austria

5 Academic Teaching Hospital, Medical University of Innsbruck, Innsbruck, Austria

6 Department of Surgery, St John of God Hospital, Graz, Austria

Published online: 05 June 2018

Author's personal copy

approach with giant prosthetic reinforcement of the visceral sac (GPRVS) was first described by Rives and Stoppa [7].

In open surgery, large pore, lightweight prostheses are associated with less chronic pain (in the first year of follow-up) without a higher recurrence rate during long term follow-up [8], but a meta-analysis of randomized controlled trials failed to show convincing evidence that this also applies to endoscopic groin hernia repair [9]. Normally, for bilateral hernias, a separate mesh is used on each side with sufficient overlap over the hernia defects [6]. Clinical evaluation of new mesh products is essential. We evaluated a novel mesh for laparoscopic treatment of bilateral inguinal hernias. This is a pre-shaped, large pore, titanium-coated, lightweight polypropylene mesh measuring 30 × 11 cm.

Materials and methods

In the period of May 1, 2015 to June 30, 2016, data were collected prospectively from all 36 patients who underwent elective surgical repair of bilateral inguinal hernias with a newly designed bilateral mesh at two Departments of General Surgery, i.e. the Congregation Hospital (Elisabethinen and Sisters of Charity), Linz, Austria, and at the St John of God Hospital, Graz, Austria. No patients with previous open preperitoneal or laparo-endoscopic preperitoneal inguinal hernia repair were included. Previous radical prostatectomy was also an exclusion criterion. All patients provided informed consent for treatment with a newly designed CE (Communauté Européenne) certified mesh and were entered in the Herniamed registry [10]. This is an Internet-based registry for the entire spectrum of hernia surgery, comprising preclinical, perioperative and follow-up data. All patients have been and will be followed up according to the Herniamed register's protocol, i.e. postoperatively, and after one, five, and ten years. Besides, this small cohort underwent structured post-operative follow-up 6 and 12 months postoperatively including a clinical examination at our outpatient departments. Recurrences, local complications and pain as reported by patients (resting or stress pain and pain requiring medication) were noted.

The TiO_2 (Biocer®, Bayreuth, Germany) mesh is a lightweight, monofilamentous polypropylene mesh with a weight of 47 g/m^2 and a pore size of 2.8 mm. The titanium dioxide coating is intended to enhance the biocompatibility of the polypropylene filaments [11]. Together with the light weight, the large-pored structure and the reduced material surface should contribute to fibroblastic ingrowth and reduced shrinkage [12]. Since no experimental or clinical studies on this special titanium-coated polypropylene mesh have as yet been published, nothing definite can be said about its efficacy [11]. The first general experience with titanized meshes in Germany was published in 2004 [13]. There were no major or mesh related complications or incompatibilities. The CE certified TiO2Mesh® is available in different sizes and shapes, as are special mesh implants for specific indications in modern hernia surgery, such as the mesh for bilateral TAPP introduced in this paper. This mesh was developed by surgeons at the Department of Surgery, St John of God Hospital, Graz, Austria (see Fig. 1a).

Surgical technique

Basically successful dissection during laparoscopic groin hernia surgery involves some crucial steps and the myopectineal orifice [14] must be exposed before the mesh is put in place. The patient empties the bladder immediately before the operation and lies supine in the Trendelenburg position with both arms secured to the sides. The operating surgeon stands at the level of the patient's head and the operation is performed with three trocars. The surgeon first incises the peritoneum of the lower abdominal wall starting near the iliac spine and continues with a curved incision to create peritoneal flaps and reach the preperitoneal space of Bogros [15]. After dissection of one side with identification of the anatomical landmarks (epigastric vessels, pubic bone, cord structures) and dissection of the hernia sac, the retropubic space must be exposed from one side of the groin to



Fig. 1 **a** Current shape of the mesh with a median slit and a 5 cm bridge. **b** Recommended mesh shape with an 8 cm broad bridge

Author's personal copy

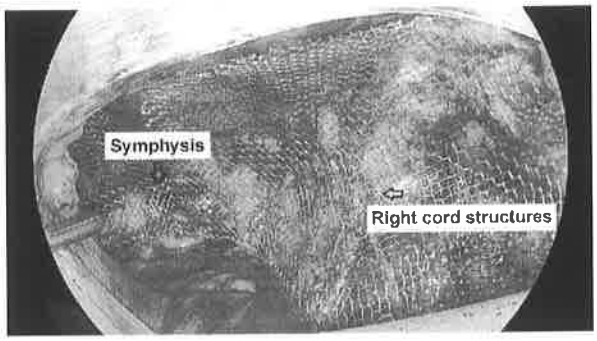

Fig. 2 Definitive mesh placement



Fig. 3 Glue fixation

the other. This can be facilitated by extending the peritoneal incision cranially and perpendicular to the medial umbilical fold. The endoabdominopelvic fascia on the lateral aspect of the groin is not opened because the nerves run deep to the fascia. Following complete dissection of one side with good exposure of the landmarks, the contralateral side is prepared in the same fashion. This is an innovation, because we used to finish one side before preparing the other. Then the bilateral mesh is inserted through the 10 mm camera trocar into the peritoneal cavity. The mesh is deployed and after proper orientation, placed in the preperitoneal space. The left part of the mesh is then passed between symphysis and bladder (retropubic space) from the right to the left side with laparoscopic forceps, and adjusted and positioned to cover all defects with sufficient overlap (Fig. 2). This maneuver alone differs from the TAPP technique with two meshes. The mesh must lie smooth without wrinkles or folds. The lower margin of the mesh should be at least 1 cm distant from the peritoneal parietalization to prevent the mesh from rolling up when the lower peritoneal flap is elevated to close the peritoneum. Adequate parietalization of the peritoneum is crucial for proper mesh placement [6]. After correct placement, the mesh is fixed with dots of cyanoacrylate glue (Resorba Liquiband FIX 8®, Nürnberg, Germany) (Fig. 3). The synthetic non-absorbable glue is applied at only a few points (5 per side) to ensure integration of the mesh material but without creating a seal. Finally the peritoneum is closed securely with a running barbed suture. The entire suture must be completely covered with tissue and finally passed through the peritoneum beside the closed incision. The end of the suture has to line-up precisely with the underlying tissue to prevent small bowel injury and/or obstructive adhesions [16].

Results

Between May 2015 and June 2017, 36 patients with bilateral inguinal hernias (72 hernia defects) underwent TAPP with a bilateral mesh. Five of them had suffered from recurrence after previous anterior tissue (Shouldice) or mesh based repair (Lichtenstein). Five surgeons with extensive experience in TAPP technique performed the operations, which were completed without intraoperative complications or conversions to open surgery. Since all of the participating surgeons had tested the mesh several times during the development process prior to the study, their learning curves rose quickly. The mean operation time was 74 min. Patient demographics, disease characteristics and relevant outcome data are presented in Table 1 [17]. Short-term patient-related outcomes were uneventful except for one case of hematoma of the spermatic cord that resolved spontaneously. All patients were advised to take an oral pain killer (NSAR) for 7 days after discharge. There were no late complications at structured post-operative follow-up 6 and 12 months postoperatively; no patients were lost to follow- up. One symptomatic medial recurrence after a previous supravesical hernia repair [18] and one medial recurrence after a previous large medial hernia (3 cm hernia orifice) treatment were seen at follow-up. Both patients underwent re-do surgery and both recurrences were due to inadequate medial mesh overlap adjacent to the mesh slit. We attribute these recurrences (5.6% of patients, 2.8% of hernia defects, respectively) mainly to insufficient medial overlap due to the mesh design with a median slit and a 5 cm bridge (Fig. 1a). This shape does not seem to be suitable to cover large medial and rare median supravesicular defects.

Discussion

Bulging of a mesh into a defect with pseudo recurrence or mesh dislocation depends on the size of the defect in relation to the structural stability of the mesh, the traction between the mesh its point of attachment, and the size of the mesh and its overlap. If a force is applied to a solid object such as a mesh surface, the pressure is defined as the force applied divided by the area of application. Of course, two superimposed meshes create a larger total area, but the resistance

Author's personal copy

Table 1 Patients' demographics, disease characteristics and outcome data

	$N=36$ (patients)
Age (years)	56
Gender (male/female)	34/2
BMI (kg/m^2)	26.3
EHS classification [17]	72 hernia defects
Medial	
M1	10
M2	9
M3	9
(Supravesical)	1
Lateral	
L1	21
L2	13
L3	9
Redo surgery after anterior groin repair	$N=5$
Number of patients with	
(a) Diabetes mellitus	2
(b) COPD	3
(c) Nicotine dependence	7
(d) Immunosuppression	1
(e) Coagulopathy	1
(f) Clopidrogel, acetylsalicyl acid, others	3
ASA score	2 (range 1–3)
Number of patients with	
(a) Intraoperative complication	0
(b) Postoperative complication	1 (spermatic cord hematoseroma)
(c) Reoperation	0
(d) Readmission	0
(e) Recurrence	2/72 hernia repairs (2.8%)
	2/36 patients (5.6%)
(f) Pain requiring treatment after dismissal (VAS > 4)	2
(g) Chronic pain requiring treatment (VAS > 4)	1
Length of hospital stay (days)	3 (range 1–7)
Duration of operation (min)	74 (range 49–119)

VAS visual analogue scale

to the force always depends only on one mesh area because the mesh margins are not connected. One larger piece of mesh theoretically provides more stable medial support and eliminates the weak point between two adjacent meshes that predisposes to mesh bulges and protrusions. It would be helpful to demonstrate the effectiveness of the new design in a mechanical model to verify that the impact of the design is relevant in relation to the other confounders.

Fixation of the mesh in laparoscopic inguinal hernia surgery is discussed controversially and atraumatic glue fixation may be preferable to penetrating fixation [19]. Patients with a medial hernia are at higher risk of recurrence than those with lateral defects. With mesh fixation and/or larger mesh size (12 × 17 cm), the recurrence rate for larger medial hernias series could be significantly reduced in a large series [20]. Accordingly, we assume that fixation might become redundant even in large medial bilateral defects when a large bilateral mesh is applied, although the ideal shape and size have yet to be determined. Even without evidence we expect that a larger adherent mesh surface will lower the risk of early bilateral mesh dislocation as caused by coughing and the Valsalva maneuver during extubation. To minimize the risk of early dislocation, some surgeons usually resort to mesh fixation when using two separate meshes for bilateral TAPP.

In our series there were two recurrences after TAPP repair of medial and supravesicular defects with bilateral meshes. These rare hernias are often misidentified as medial hernias and not included in the current classifications. External protrusions of the supravesical fossa are surrounded by the

Author's personal copy

transverse vesical fold, median umbilical fold, and medial umbilical fold [18]. Because of the central slit the current shape of the bilateral mesh does not seem to be suitable for repairs of such very medial defects. Stoppa and Rives chose a subperitoneal median approach to perform a giant prosthetic bilateral reinforcement of the visceral sac, covering Fruchaud's myopectineal orifice preperitoneally with extensive overlap [7]. The rhomboid mesh had no slit and enclosed the whole peritoneal sac. These early findings suggest a mesh with a different shape and only a small slit at the midline (Fig. 1b) that would still provide sufficient overlap for medial and supravesical hernias. An additional larger size should be offered (34 × 12 cm) for combined lateral and medial defects on both sides, especially for taller individuals. The mesh should be less rounded and more rectangular. For comparison, the one year follow-up of our Herniamed register data of 241 bilateral TAPP procedures using two pieces of 15 × 10 cm meshes overlapping in the midline showed a recurrence rate of 0.83%.

Accurate medial retropubic and prevesical dissection is one of the key points of the TAPP procedure [6, 14, 15, 20]. During training residents should learn to deal with the bilateral mesh because proper medial dissection is a prerequisite for correct mesh placement. If they use two meshes and leave a space between them, correct medial dissection is not assured. The operation time for TAPP procedures with the bilateral mesh averaged 74 min. We assume that bilateral mesh placement might be easier and faster with one large mesh rather than two small ones that require repetition of some steps of the procedure.

In summary, the concept of one large mesh for laparoscopic bilateral inguinal hernia repair is new. Our relatively small study with significant early recurrence rate is not strong enough to support this technique, at least not with the current mesh design. The results of our study suggest that a newly designed bilateral mesh for TAPP needs a change in shape to provide theoretical advantages for the treatment of bilateral inguinal hernias with the benefit of offering more resistance to the forces pressing on the mesh that can cause mesh dislocation, mesh bulge into a hernia, and recurrence. One large piece of mesh may provide more stable support than two separate meshes overlapping at the midline. In its present shape, however, the central slit in the new mesh could be a disadvantage with medial defects, which would better be covered with a mesh with a broad central junction between the two sections of the mesh. After the mesh has been re-designed, a new study should be performed to evaluate its real benefits before it is put on the market.

Compliance with ethical standards

Conflict of interest G. K. has received honorariums from Medtronic, Dahlhausen and Bard for lectures and educational activities. I. F. declares no conflict of interest. No competing financial interests exist. R. K. declares no conflict of interest. No competing financial interests exist. M. M. declares no conflict of interest. No competing financial interests exist. G. S. has received honorariums from Medtronic and AFS-Medical for lectures und educational activities outside this work. AFS is the company marketing the T02 mesh but the honorariums was not paid for suggesting changes in mesh configurations and mesh development. A. S. has received honorariums from Medtronic and AFS-Medical for lectures und educational activities outside this work. AFS is the company marketing the T02 mesh but the honorariums was not paid for suggesting changes in mesh configurations and mesh development.

Ethical approval No ethical approval was required for this study.

Human and animal rights This article does not contain any studies with animals performed by any of the authors.

Informed consent All patients provided informed consent for treatment with the newly designed CE certified mesh and TAPP procedure.

References

1. Fitzgibbons RJ Jr, Forse RA (2015) Clinical practice. Groin hernias in adults. N Engl J Med 372:756–763
2. Pahwa HS, Kumar A, Agarwal P, Agarwal AA (2015) Current trends in laparoscopic groin hernia repair: a review. World J Clin Cases 3(9):789–792
3. McCormack K, Scott N, Go PM, Ross SJ, Grant A (2003) Collaboration the EU Hernia Trialists Laparoscopic techniques versus open techniques for inguinal hernia repair. Cochrane Database Syst Rev. https://doi.org/10.1002/14651858.CD001785
4. Pfeffer F, Riediger H, Küfner Lein R, Hopt UT (2008) Repair of bilateral inguinal hernias—sequential or simultaneous? Zentralbl Chir 133(5):446–451 (**article in German**)
5. Wolloscheck T, Konerding MA (2009) Dimensions of the myopectineal orifice: a human cadaver study. Hernia 13(6):639–642
6. HerniaSurge Group (2018) International guidelines for groin hernia management. Hernia 22(1):1–165
7. Stoppa R, Petit J, Abourachid H, Henry X, Duclaye C, Monchaux G, Hillebrant JP (1973) Original procedure of groin hernia repair: interposition without fixation of Dacron tulle prosthesis by subperitoneal median approach. Chirurgie 99(2):119–123 (**French**)
8. Bury K, Smietanski M (2012) 5-year results of a randomized clinical trial comparing a polypropylene mesh with a poliglecaprone and polypropylene composite mesh for inguinal hernioplasty. Hernia 16(5):549–553
9. Currie A, Andrew H, Tonsi A, Hurley PR, Taribagil S (2012) Lightweight vs. heavyweight mesh in laparoscopic inguinal hernia repair: a meta-analysis. Surg Endosc 26(8):2126–2133
10. Stechemesser B, Jacob DA, Schug-Paß C et al (2012) Herniamed: an internet-based registry for outcome research in hernia surgery. Hernia 16(3):269–276
11. Köckerling F, Schug-Pass C (2014) What do we know about titanized polypropylene meshes? An evidence-based review of the literature. Hernia 18(4):445–457
12. Zhu LM, Schuster P, Klinge U (2015) Mesh implants: an overview of crucial mesh parameters. World J Gastrointest Surg 27(10):226 236 7(
13. Sardey HM1, Schopf S, Rudert W, Knappich P, Hernandez-Richter T (2004) Titanised polypropylene meshes: first clinical experience with the implantation in TAPP technique and the results of a survey in 22 German surgical departments [article in German]. Zentralbl Chir 129(5):363–368

Author's personal copy

14. Daes J, Felix E (2017) Critical view of the myopectineal orifice. Ann Surg 266:c1–c2
15. Bendavid R (1992) The space of Bogros and the deep inguinal venous circulation. Surg Gynecol Obstet 174(5):355–358
16. Köhler G, Mayer F, Lechner M, Bittner R (2015) Small bowel obstruction after TAPP repair caused by a self-anchoring barbed suture device for peritoneal closure: case report and review of the literature. Hernia 19(3):389–394
17. Miserez M, Alexandre JH, Campanelli G et al (2007) The European hernia society groin hernia classification: simple and easy to remember. Hernia 11(2):113–116
18. Lee SR (2017) Clinical characteristics and laparoscopic treatment of supravesical hernia. J Laparoendosc Adv Surg Tech A 27(11):1192–1197
19. Antoniou SA, Köhler G, Antoniou GA, Muysoms FE, Pointner R, Granderath FA (2016) Meta-analysis of randomized trials comparing nonpenetrating vs mechanical mesh fixation in laparoscopic inguinal hernia repair. Am J Surg 211(1):239–249
20. Mayer F, Niebuhr H, Lechner M et al (2016) When is mesh fixation in TAPP-repair of primary inguinal hernia repair necessary? The register-based analysis of 11,230 cases. Surg Endosc 30(10):4363–4371

San José, 28 de Julio 2020
AC-361-2020

LICITACIÓN ABREVIADA
2020LA-000061-2102 "MALLAS DE POLIÉSTER, DISPOSITIVO ABSORBIBLE PARA FIJACIÓN DE MALLAS PARA REPARACIÓN DE HERNIAS"
SUBÁREA DE CONTRATACIÓN ADMINISTRATIVA
HOSPITAL SAN JUAN DE DIOS
CCSS

El suscrito, **Nerio David Mavarez Iriarte,** Venezolano, de profesión Economista, Casado, y vecino de Santa Ana, con cédula de residencia 186200441125, en mi condición de Apoderado Generalísimo sin límite de suma de **EUROCIENCIA COSTA RICA SOCIEDAD ANÓNIMA,** con cédula de persona jurídica número tres-ciento uno-cuatrocientos sesenta y seis mil novecientos dieciocho, con el debido respeto me presento a manifestar lo siguiente

De conformidad con lo dispuesto artículos 5, 81, 82 y 83 de la Ley de Contratación Administrativa y en los artículos 172 y 173 del Reglamento a la Ley de Contratación Administrativa, interpongo **Recurso de Objeción** al Cartel **2020LA-000061-2102 "MALLAS DE POLIÉSTER, DISPOSITIVO ABSORBIBLE PARA FIJACIÓN DE MALLAS PARA REPARACIÓN DE HERNIAS"** promovida por el Hospital San Juan de Dios.

Primero: Legitimación: Mi representada está inscrita como Proveedor ante la C.C.S.S, bajo el Nº 21659, siendo Representante Exclusivo de los productos BD BARD para Costa Rica, Compañía de alta trayectoria , por lo cual tenemos legítimo interés de participar en el presente concurso.

También amparados en la Ley de Contratación Administrativa Artículo 5.-Principio de igualdad y libre competencia.

"En los procedimientos de contratación administrativa, se respetará la igualdad de participación de todos los oferentes potenciales. Los reglamentos de esta Ley o las disposiciones que rijan los procedimientos específicos de cada contratación, no podrán incluir ninguna regulación que impida la libre competencia entre los oferentes potenciales.

La participación de oferentes extranjeros se regirá por el principio de reciprocidad, según el cual a ellos se les brindará el mismo trato que reciban los nacionales en el país de origen de aquellos. El Poder Ejecutivo establecerá, reglamentariamente, las disposiciones necesarias para la vigencia plena del principio estipulado en este párrafo.

Los carteles y los pliegos de condiciones no podrán disponer formas de pago ni contener ninguna regulación que otorgue a los oferentes nacionales un trato menos ventajoso que el otorgado a los oferentes extranjeros".

Segundo: Fecha de la publicación del Cartel: El Cartel de esta contratación se publicó el día 23 de julio de 2020.

Tercero: Plazo para presentación de las ofertas: El plazo para presentar las ofertas vence el día 7 de agosto del año en curso.

Cuarto: Objeto de la contratación: Es el suministro de **"MALLAS DE POLIÉSTER, DISPOSITIVO ABSORBIBLE PARA FIJACIÓN DE MALLAS PARA REPARACIÓN DE HERNIAS"**
Quinto: Especificaciones Técnicas objeto del recurso: Las siguientes son las especificaciones técnicas que solicitamos modificar:

ITEM 2 "Malla de poliéster tridimensional uso laparoscópico de 25 X 20 cm".

El cartel solicita para este ítem:

1. **"Malla de poliéster tridimensional".**

2. **"Componente hidrofílico absorbible de colágeno, glicol de polietileno y glicerol para evitar adherencias y permitir el contacto con vísceras".**
3. **Tamaño del poro de 2,55 mm x 1,73 mm**
4. **Grosor de la malla 1,5 a 2 mm**

La malla de la casa que representa Eurociencia es de polipropileno y tiene un diseño elipse. Ver Anexo 1.

La malla de la casa que representa Eurociencia está hecha de monofilamento de polipropileno y posee hidrogel formado por **hialuronato de sodio (HA), Carboximetilcelulosa (CMC) y Polietilenglicol (PEG). -Unidas entre sí por ácido poliglicólico (PGA),** lo cual es absorbible y puede estar en contacto con las vísceras tal y como lo solicita el cartel

Las medidas de la malla Ventralight son:
Tamaño de poro de 2 mm
Grosor de la malla de 0,57 mm

Justificación: En relación a este punto, hacemos referencia a las "GUIAS DE PRÁCTICA CLÍNICA PARA HERNIAS DE LA PARED ABDOMINAL", de la Asociación Mexicana de Hernias, actualización Mayo 2009, la cual en su apartado #3 MATERIALES PROTESICOS, puntos 1, 3 y 5 refiere:

> *"1.- Existe suficiente evidencia para confirmar que en la actualidad la prótesis de malla que más se acerca a la ideal de acuerdo a los criterios de Cumberland* ***es la malla de monofilamento de polipropileno ligera*** *(el resaltado es nuestro) o reducida pues contiene hasta 70% menos de material que sus antecesores de polipropilenos pesados. Su fuerza tensíl es más parecida a la abdominal (20 N/cm contra 16 N/cms de la pared abdominal) produce menor restricción de movimiento (compliance) en el post-operatorio al colocar grandes segmentos en la pared del abdomen, su tamaño del poro mayor permite transparencia de los tejidos evitando lesiones vasculares o nerviosas al momento de su fijación y permitiendo una migración y proliferación de fibroblastos y angioblastos adecuada, lo que se traduce en mejor integración de la misma a los tejidos propios.*

Con respecto a las medidas, no afectan ni la técnica de cirugía ni el resultado de la misma. La malla ofertada por Eurociencia ha sido utilizada a nivel privado con excelentes resultados.

PETITORIA:

Por lo anteriormente expuesto, respetuosamente solicitamos se amplie la especificación indicada de la siguiente manera

1. **"Malla de poliéster tridimensional o polipropileno elipse.**

2. "Componente hidrofílico absorbible de colágeno, glicol de polietileno y glicerol para evitar adherencias y permitir el contacto con vísceras".
3. Tamaño del poro de 2,55 mm x 1,73 mm o 2 mm x 2 mm
4. Grosor de la malla 0,57 a 2 mm

ITEM 3 "Dispositivo absorbible para fijación de mallas para reparación de hernias. Dispositivo de 36 cm para fijación de mallas en abordaje laparoscópico".

El cartel solicita para este ítem:
"Dispositivo de 36 cm para fijación de mallas en abordaje laparoscópico".
"Cargados por clips compuestos al menos de copolímero de ácido glicólico y láctico, absorbibles, para utilizar con trócar al menos de 5 mm".
"Dispositivo con 20 a 25 clips".

El dispositivo de fijación de la casa que representa Eurociencia es de 39 cm lo cual da mayor flexibilidad al posicionamiento y acceso en la cavidad, es de ácido poliláctico y ácido poliglicólico, absorbibles, tal como lo solicita el cartel. En Optifix tenemos dispositivo con 15 o con 30 "tachuelas", Ver Anexo 2.

La diferencia en el tamaño es de 3 cm, para las dimensiones respectivas con el rango solicitado en el cartel y demás características descritas. Además la cantidad de tachuelas, que en nuestro caso son de 15 o 30 unidades, esto permite ser utilizado de acuerdo al tamaño del defecto proveyendo versatilidad y flexibilidad.

Justificación: Respetuosamente consideramos que el largo de este dispositivo no afecta de ninguna manera el desempeño o los resultados quirúrgicos, por lo cual no afecta el objeto de la contratación. Además el diseño le permite adaptarse con facilidad a la anatomía.

PETITORIA:

Por lo anteriormente expuesto, respetuosamente solicitamos se amplie la especificación indicada de la siguiente manera

"Dispositivo de 36 +/- 3 cm para fijación de mallas en abordaje laparoscópico".
"Cargados por clips o tachuelas compuestos al menos de copolímero de ácido glicólico y láctico, absorbibles, para utilizar con trocar al menos de 5 mm".
"Dispositivo con 20 a 30 clips o tachuelas".

Quedamos a sus órdenes para cualquier aclaración adicional.

Se despide atentamente,

NERIO DAVID MAVAREZ IRIARTE (FIRMA)

Firmado digitalmente por NERIO DAVID MAVAREZ IRIARTE (FIRMA)
Fecha: 2020.07.28 10:35:15 -06'00'

Nerio Mavarez Iriarte
Apoderado Generalísimo
Eurociencia Costa Rica, S.A

Presentamos la malla ST VENTRALIGHT™

La nueva generación de reparación laparoscópica de la hernia ventral

NEW



Tecnología Sepra®

- Basada en la tecnología utilizada en Seprafilm® durante más de 13 años de éxito clínico demostrado.
- La exclusiva barrera de hidrogel se hincha para reducir al mínimo el riesgo de adhesión tisular a la cara visceral de la malla.[1]
- Las fibras PGA bioreabsorbibles refuerzan toda la barrera de hidrogel uniéndola a la malla de polipropileno.
- Transcurridos 30 días, la barrera de hidrogel se reabsorbe, facilitando la protección visceral durante el crítico periodo de cicatrización.



1. Datos preclínicos archivados en C. R. Bard. Puede que los resultados no tengan correlación con su evolución en humanos.

Tecnología Sepra® probada en mallas de bajo peso y perfil

Eficiente:

- Gracias a su diseño de bajo perfil, la disposición de los trócares y la fijación mecánica resultan más fáciles.
- Puede cortarse según el tamaño y la forma que se necesite.

Eficaz:

- La malla de polipropileno monofilar de bajo peso sin recubrimiento permite la integración tisular completa, con un riesgo mínimo de contracción favoreciendo así una reparación sólida.
- La barrera de hidrogel reduce al mínimo la adhesión tisular a la cara visceral de la malla.

The VENTRALIGHT™ ST polypropylene mesh is approximately 50% lighter than traditional polypropylene mesh.



Comprobado:

- La barrera de hidrogel está basada en la Tecnología Sepra®.
- Polipropileno monofilar.
- En cirugía general se han utilizado estos dos materiales durante años, con éxito clínico comprobado.

Entre otras complicaciones pueden surgir las siguientes: seroma, adhesiones, hematomas, inflamación, extrusión, fístulas, infecciones, reacciones alérgicas y recidiva de la hernia o defectos del tejido blando.

BARD
DAVOL INC.

TECHNOLOGY
TECHNIQUE
TRAINING
TRUST



Catalog Number	Description	Sizes	Quantity
5954450	Circle	11.4 cm (4.5")	1/cs
5954460	Ellipse	10.2 cm x 15.2 cm (4" x 6")	1/cs
5954680	Ellipse	15.2 cm x 20.3 cm (6" x 8")	1/cs
5954610	Oval	15.2cm x 25.4cm (6" x 10")	1/cs
5954790	Ellipse	17.8 cm x 22.9 cm (7" x 9")	1/cs
5954810	Ellipse	20.3 cm x 25.4 cm (8" x 10")	1/cs
5954113	Ellipse	25.4 cm x 33 cm (10" x 13")	1/cs
5954124	Rectangle	30.5 cm x 35.6 cm (12" x 14")	1/cs

Anexo 1

Bard France S.A.S
(France, North Africa)
FRANCE
Tel: + 33 1 39 30 58 58
Fax: + 33 1 39 30 58 59

Bard de España S.A.
(Spain, Portugal)
SPAIN
Tel: + 34 93 253 7800
Fax: + 34 93 253 7834

Bard S.p.A
(Italy, Eastern Mediterranean, Middle East)
ITALY
Tel: + 39 06 52 49 31
Fax: + 39 06 529 58 52

Bard Medica S.A.
SWITZERLAND
Tel: + 41 44 722 5360
Fax: + 41 44 722 5370

Bard Limited
(UK, Ireland)
UNITED KINGDOM
Tel: + 44 1293 527688
Fax: + 44 1293 582428
customer.services@crbard.com

Bard Czech Republic s.r.o.
CZECH REPUBLIC
Tel: + 420 242 408 630
Fax: + 420 242 410 185

Bard Benelux N.V.
BELGIUM
Tel: + 32 14 28 69 52
Fax: + 32 14 28 69 66
custservicebelgium@crbard.com

THE NETHERLANDS
Tel: + 31 30 60 00 572
Fax: + 31 30 60 22 345
custservicenederland@crbard.com

Bard Poland Sp.z o.o.
POLAND
Tel: + 48 22 321 09 30
Toll Free: 0800 494900
Fax: + 48 22 321 09 38
Toll Free: 0800 494901

Bard Hellas SA
GREECE
Tel: + 30 210 96 00 780 1
Fax: + 30 210 96 28 810

C. R. Bard GmbH
GERMANY
Tel: + 49 721 9445 124
Fax: + 49 721 9445 100

Bard Medical Systems Norden AB
SWEDEN
Tel: + 46 42 386 000
Fax: + 46 42 386 010

NORWAY
Tel: + 47 815 00 266
Fax: + 47 815 00 299

DENMARK
Tel: + 45 49 26 20 08
Fax: + 45 49 26 20 09

FINLAND
Tel: + 358 9 547 30 53
Fax: + 358 9 546 25 76

Bard Medica S.A.
AUSTRIA
Tel: + 43 1 49 49 130
Fax: + 43 1 49 49 130 30

Bard Medical SA (Pty) Ltd.
SOUTH AFRICA
Tel: + 27 115 24 9900
Fax: + 27 86 537 7250

Asegúrese de leer la etiqueta y el prospecto del producto para consultar cualquier contraindicación, riesgo o advertencia; las precauciones a tomar y las instrucciones de uso.

Datos predicativos archivados en C. R. Bard. Puede que los resultados no tengan correlación con su experiencia en humanos.
Bard, Davol y Ventralight son marcas o marcas registradas de C. R. Bard, Inc.
Sepra y Sepramesh son marcas registradas de Genzyme Corporation autorizadas para C.R. Bard, Inc.
© Copyright 2011, C. R. Bard, Inc. Reservados todos los derechos. 0211/2809

VENTRALIGHT™ ST Mesh is just one in a complete family of hernia repair products:

Ventral Hernia Repair Products

VENTRALEX™ Hernia Patch
COMPOSIX™ L/P Mesh
COMPOSIX™ KUGEL™
VENTRIO™ Hernia Patch
SEPRAMESH™ IP Composite
DULEX™ Mesh
COLLAMEND™ FM Implant
XENMATRIX™ Surgical Graft

Inguinal Hernia Repair Products

PERFIX™ Plug
PERFIX™ Light Plug
3DMAX™ Mesh
3DMAX™ Light Mesh
MK™ Patch
BARD® Soft Mesh
VISILEX™ Mesh
BARD® Mesh Flats and Pre-Shapes
POLYSOFT™ Patch
KUGEL™ Patch

Specialty Products

CK™ Parastomal Hernia Patch
CRUROSOFT™ Patch

Fixation Products

SORBAFIX™ Absorbable Fixation System
PERMAFIX™ Permanent Fixation System
PERMASORB™ Disposable Fixation Device

BARD® Surgical Services

Clinical Education Programmes

National education centers offering instruction in surgical techniques and the ability to view live surgery are available for many of the BARD® hernia repair products. Please ask your representative for more information.

BARD® Didact
Where Knowledge Leads

BARD
DAVOL INC.

www.herniainfo.com
www.davol.com

86

OptiFix™
Absorbable Fixation System

BARD
DAVOL INC.

Absorbable Fixation Redefined

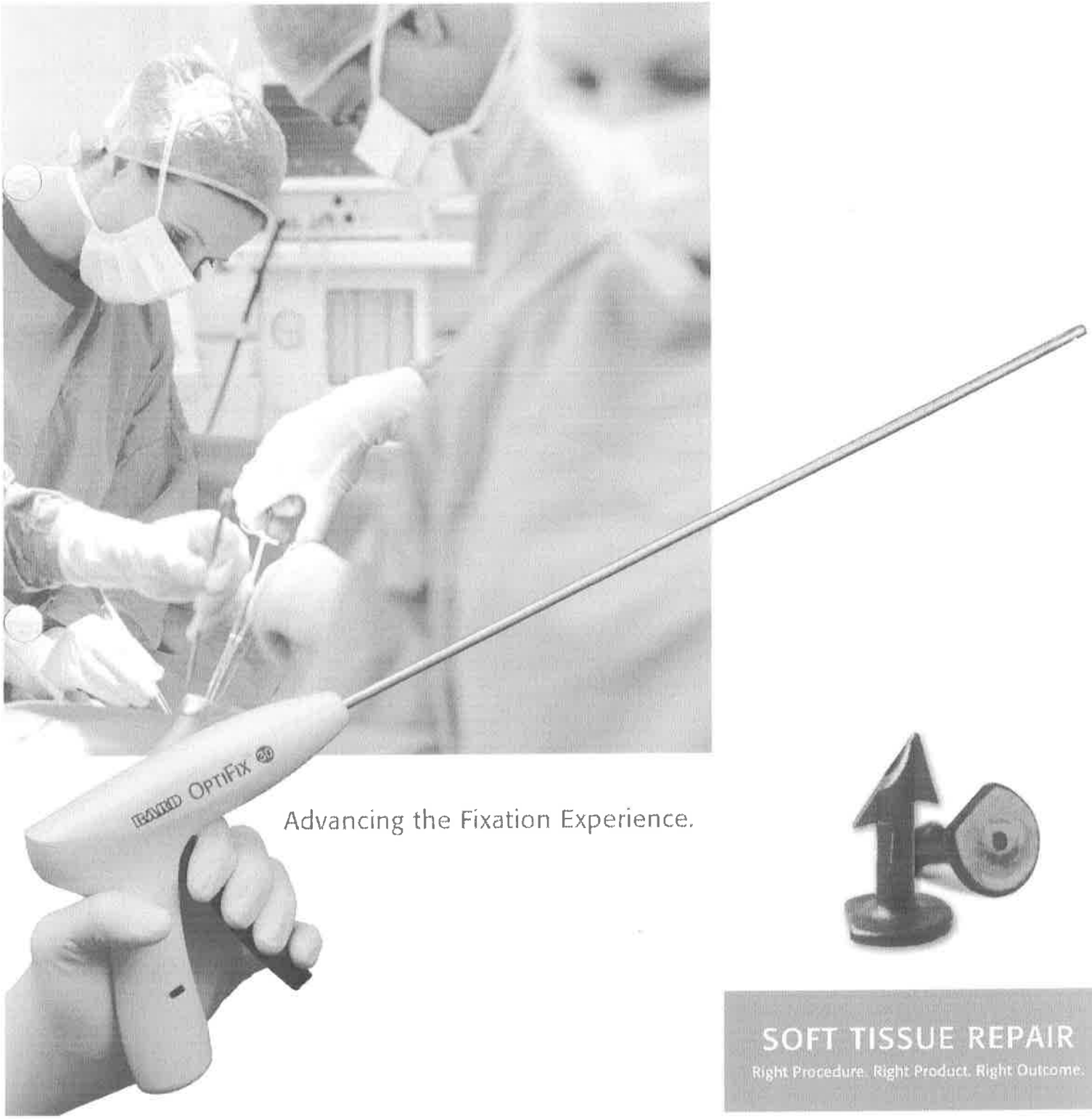

Advancing the Fixation Experience.

SOFT TISSUE REPAIR

Right Procedure. Right Product. Right Outcome.

Challenges and Opportunities in Absorbable Fixation

Absorbable Fixation devices can provide important benefits and lead to repeatable outcomes. However, Absorbable Fixation devices that facilitate soft tissue repair may also be associated with certain challenges, such as:

- Excessive deployment force may cause tissue trauma and bleeding[1]
- Fasteners may be difficult to see laparoscopically potentially leading to the placement of unnecessary fasteners
- Device may be uncomfortable or awkward to deploy in smaller sized hands and may be sensitive to surgeon technique

OPTIFIX™ Absorbable Fixation System

Surgeon confidence through a performance-driven system

The OPTIFIX™ Absorbable Fixation System has been engineered inside and out to provide surgeon confidence and secure fixation in a reliable, easy to use, and ergonomic design.

30 and 15
Available in both 30 and 15 fastener count options

Spring Loaded Trigger

- Releases stored energy to smoothly deliver fasteners through mesh and into tissue with a lower counterpressure requirement than other fixation devices
- Ensures consistent fastener deployment

Comfort Grip Handle
Designed to fit a wide range of surgeon hand sizes

Outcome-driven fixation

The OPTIFIX™ Absorbable Fastener is made from PDLLA and is designed for optimal performance. Fastener features include:

Smooth Fastener Head
- Minimizes the potential for tissue attachment[1]
- Ensures mesh is securely fixated

Hollow Core Design
- Allows tissue ingrowth through the fastener[1]

Angled Tip
- Easily penetrates mesh and tissue

Stabilizers
- Enhances tissue holding strength
- Prevents the fastener from backing out

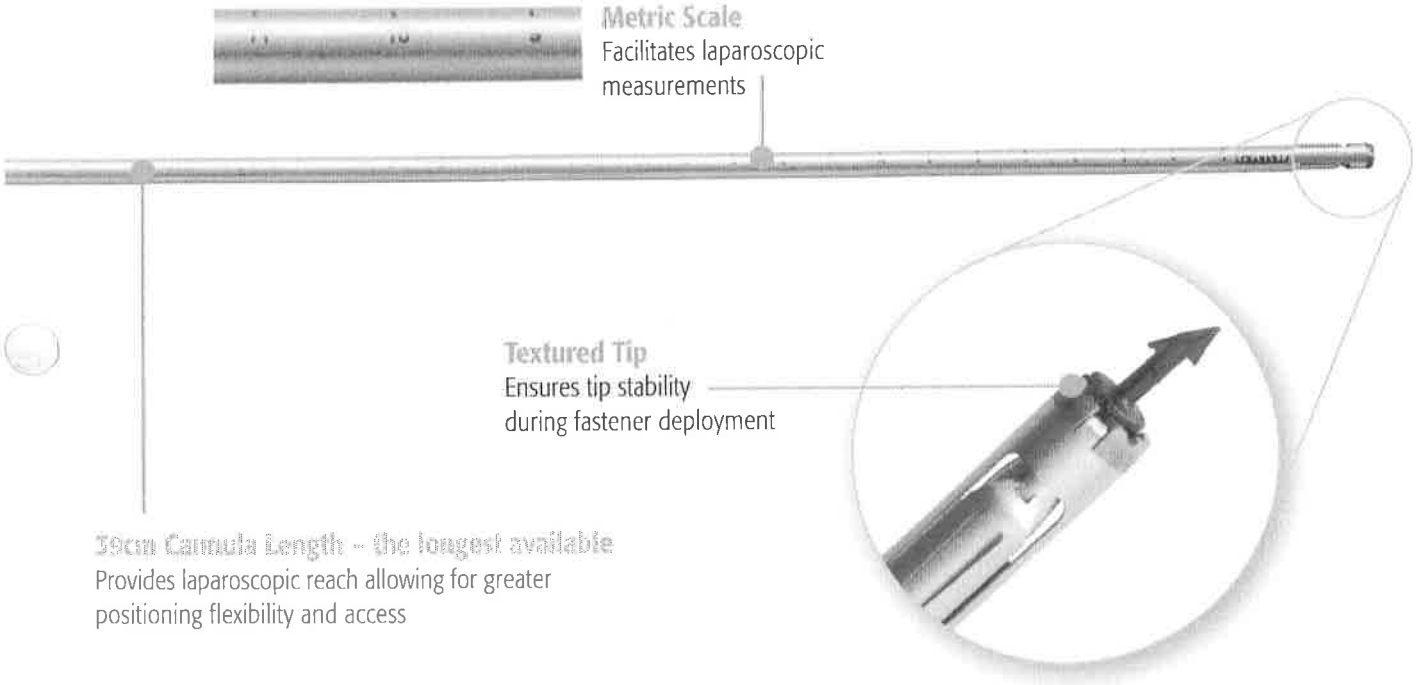

1 Preclinical data on file. Results may not correlate to clinical outcomes.

Optimally designed Fixation System for outcome-driven results

Fixate with Confidence

OptiFix™ fasteners provide secure fixation during the postoperative healing period then slowly resorbs over time

Baseline Strength Retention[2]

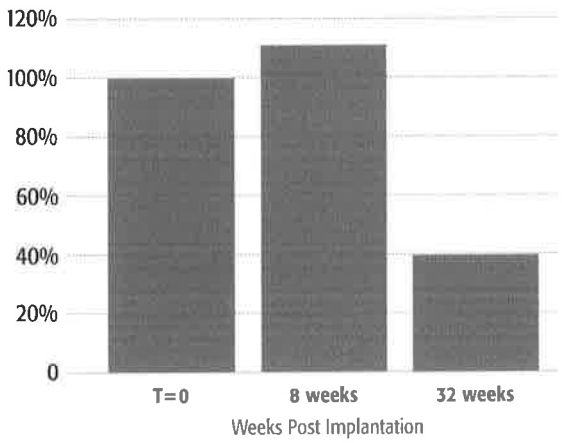

OptiFix™ Fastener maintains its strength through the crucial healing period, then begins to resorb.

Burst Pressure Over Time in a Porcine Model[3]

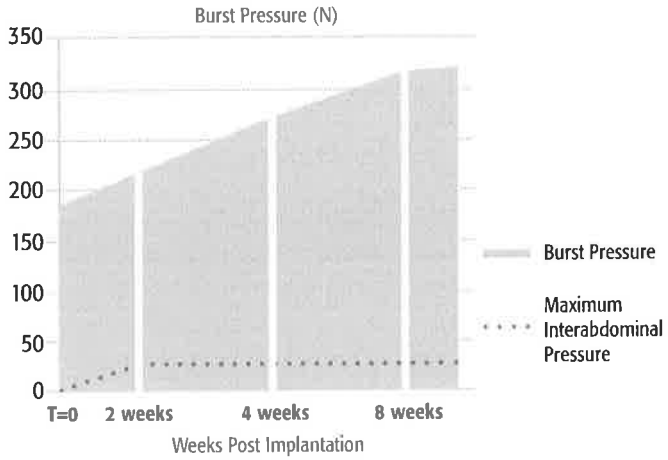

Minimal degradation of the fastener during the healing period, along with aggressive tissue ingrowth maintains burst pressures at approximately 7x the Intra-abdominal Pressure (IAP) requirement needed for the repair.

See the Difference

Fastener Visibility and Mesh Retention Surface Area

5X magnification[2]

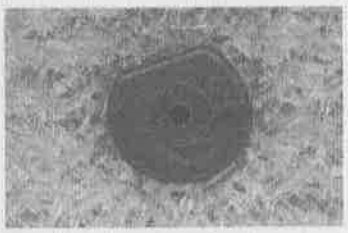

OptiFix™
9.0 mm²

AbsorbaTack™
8.6 mm²

SecureStrap™
1.8 mm²

Higher fastener surface area coverage results in more visible fasteners and more secure mesh fixation[2].

2 C.R. Bard Inc., bench data on file.
3 Preclinical data on file. Results may not correlate to clinical outcomes.

Controlled Deployment

Optimized deployment force and fastener head geometry ensures secure fixation and may minimize trauma and bleeding.

In a preclinical study, OptiFix™ demonstrated significantly less fastener site hemorrhaging than SecureStrap™. OptiFix™ experienced 9X less incidents of bleeding than SecureStrap™[2].

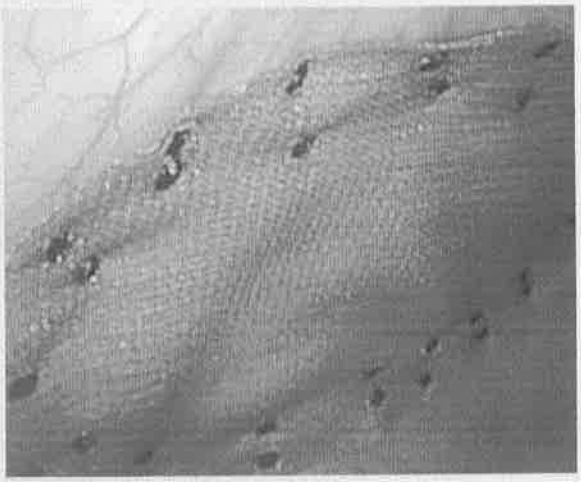

OptiFix™ with Ventralight™ ST



SecureStrap™ with PhysioMesh™ ST

The larger head of OptiFix™ reduces stress



OptiFix™ has 5X more mesh retaining surface than SecureStrap™[2]

2 C.R. Bard Inc., bench data on file.

OptiFix™ is engineered inside and out to provide surgeon confidence

Fixate with Confidence

Preferred Ergonomic Feel and Design

Surgeon Feedback[4]

Surgeons prefer the handling of OptiFix™ versus other fixation devices

In a blind preference test assessing surgeons' preference of device comfort, trigger force, and overall fit, feel and fire, OptiFix™ was preferred nearly 4x more frequently than the next closest competitor.

Overall Preference for Fit, Feel and Fire

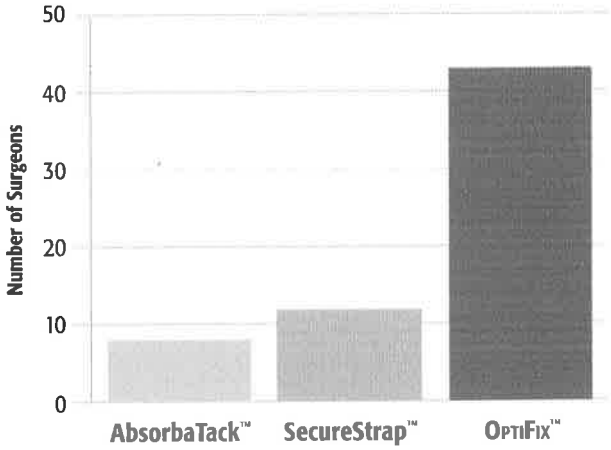

A fixation device designed with the surgeon and patient in mind.

Point of Tissue Penetration Comparison

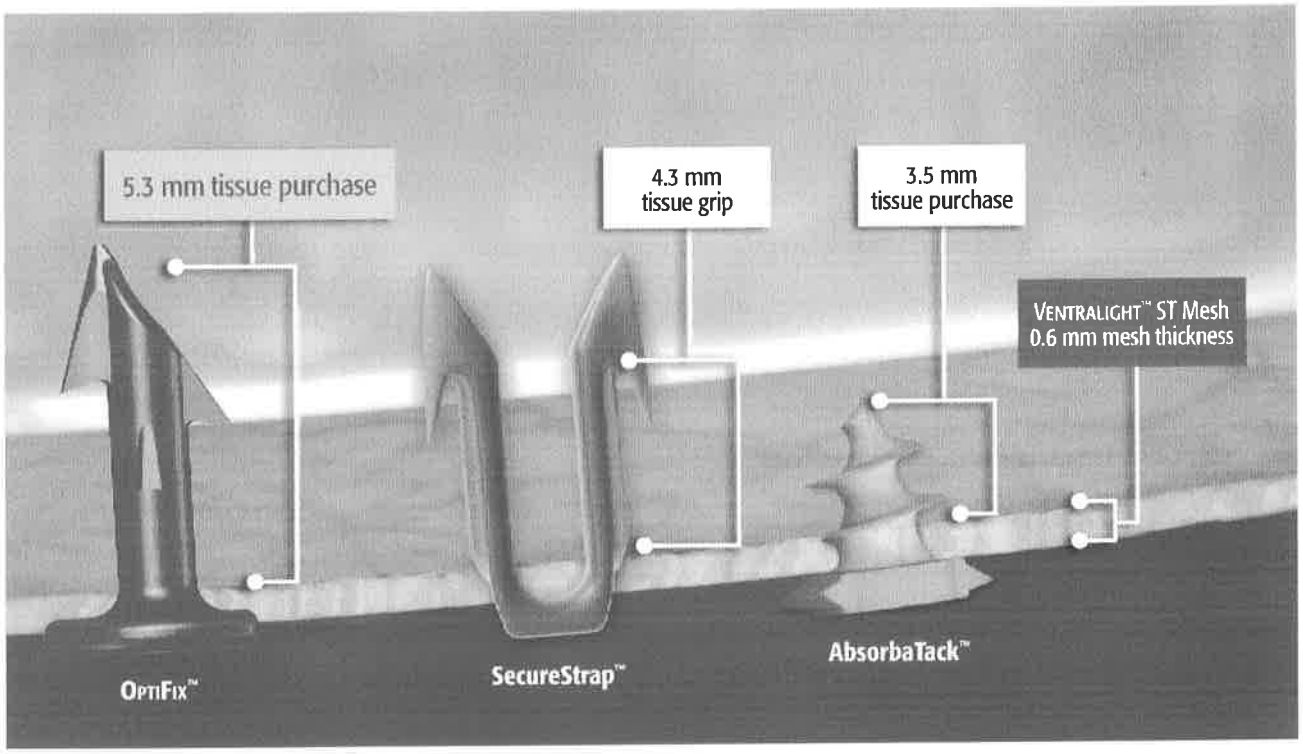

4 Survey of surgeons attending an international surgical conference. Data on file.

OptiFix™ supports your procedure of choice.

With Ventralight™ ST Mesh with Echo PS™ Positioning System in Laparoscopic Ventral Procedures

- Provides secure fixation in laparoscopic ventral procedures
- Penetrates and holds larger pore mesh as well as dual layer and/or smaller pore mesh
- Compatible in lap ventral with all Bard® mesh configurations including Ventralight™ ST, Composix™ L/P, and Ventrio™ ST

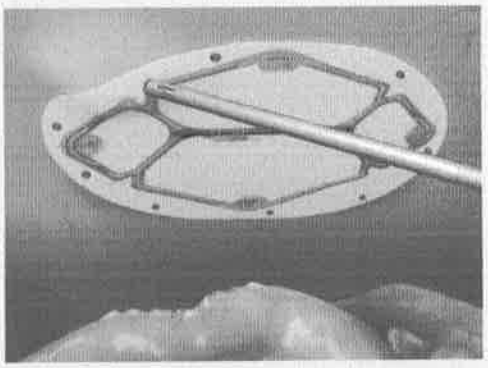

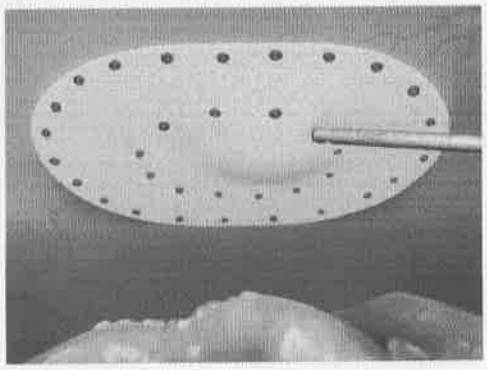

OptiFix™ Absorbable Fixation System

Indications

The OptiFix™ Absorbable Fixation System is indicated for the approximation of soft tissue and fixation of surgical mesh to tissues during open or laparoscopic surgical procedures, such as hernia repair.

Contraindications

1. Contraindications associated with laparoscopic and open surgical procedures relative to mesh fixation apply, including but not limited to:
   - Fixation of vascular or neural structures
   - Fixation of bone and cartilage
   - Situations with insufficient ingrowth of tissue into the mesh over time, which could result in inadequate fixation once the fastener is absorbed.
2. Carefully inspect the area in the vicinity of the tissue being fastened to avoid inadvertent penetration of underlying structures such as nerves, vessels, viscera or bone. Use of the OptiFix™ Absorbable Fixation System in the close vicinity of such underlying structures is contraindicated. For reference, the length of the fastener below the fastener head is 6.1 mm, the fastener head is another 0.6 mm (total 6.7 mm).

Warnings

1. The device may not fixate through prosthetics derived from biologic material such as xenografts and allografts. Prosthetic should be evaluated for compatibility prior to use. After use, the OptiFix™ Absorbable Fixation System may be a potential biohazard. Handle and dispose of in accordance with any local and federal laws regarding medical waste.

Adverse Reactions

Adverse reactions and potential complications associated with fixation devices such as the OptiFix™ Absorbable Fixation System may include, but are not limited to the following: hemorrhage; pain, edema and erythema at wound site; allergic reaction to Poly(D, L)-lactide; infection/septicemia; hernia recurrence/wound dehiscence.

Ventralight™ ST Mesh with Echo PS™ Positioning System

Indications

Ventralight™ ST Mesh is indicated for use in the reconstruction of soft tissue deficiencies, such as for the repair of hernias.

The Echo PS™ Positioning System is intended to be used to facilitate the delivery of soft tissue prostheses during laparoscopic hernia repair.

Contraindications

1. Do not use the Ventralight™ ST Mesh with Echo PS™ Positioning System in infants or children whereby future growth will be compromised by use of such material.
2. Do not use Ventralight™ ST Mesh with Echo PS™ Positioning System for the reconstruction of cardiovascular defects.
3. Literature reports there may be a possibility for adhesion formation when the polypropylene is placed in direct contact with the bowel or viscera.

Warnings

1. If an infection develops, treat the infection aggressively. Consideration should be given regarding the need to remove the prosthesis. An unresolved infection may require removal of the prosthesis.
2. Do not apply sharp, heat emitting, or ultrasonic tools (such as scissors, needles, fastenerers, diathermic tools, etc.) to the Echo PS™ Positioning System.
3. Ventralight™ ST Mesh is the only permanent implant component of the device. The inflation adapter and syringe are to be kept external to the patient and discarded after use. The Echo PS™ Positioning System (including the balloon, all connectors, and inflation tube) is to be removed from the patient and appropriately discarded as it is not part of the permanent implant.

Precautions

1. Do not trim the mesh. This will affect the interface between the mesh and positioning system.

Adverse Reactions

Possible complications include seroma, adhesions, hematomas, inflammation, extrusion, fistula formation and recurrence of the hernia or soft tissue defect.

OPTIFIX™ Absorbable Fixation System

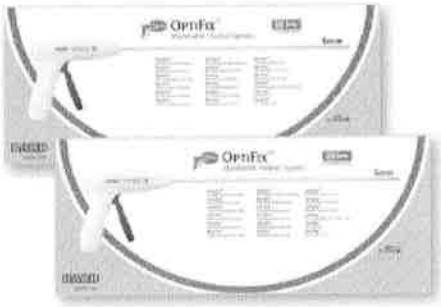

OPTIFIX™ Absorbable Fixation System

Catalog Number	Configuration	Qty	
0113126	30 Absorbable Fasteners	5/case	☐
0113127	15 Absorbable Fasteners	5/case	☐

Anexo 2

Order Form

☐ Please add these marked products to my preference card.
☐ I would like to have these marked products in stock. (Reference catalog numbers checked)
☐ I would like to trial these marked products.

Purchase Order Number _____ Date _____

Catalog Number(s) _____ Quantity _____

Surgeon's Signature _____

To learn more, contact your local BARD Representative or call 1.800.556.6275.

Please consult product labels and inserts for any indications, contraindications, hazards, warnings, precautions and instructions for use.

Bard, Davol, Echo, OptiFix, Ventralight, Composix and Ventrio are trademarks and/or registered trademarks of C. R. Bard, Inc. All other trademarks are the property of their respective owners.

© Copyright 2015, C. R. Bard, Inc. All Rights Reserved.

Davol Inc. • Subsidiary of C. R. Bard, Inc.
100 Crossings Boulevard • Warwick, RI 02886
1.800.556.6275 • www.davol.com
Medical Services & Support 1.800.562.0027
DAV/OPFX/0315/0012(2)

BARD
DAVOL INC.